

# **Molecular Breast Marker**

*Michael T. Nelson, M.D.*  
*University of Minnesota*  
*Department of Radiology*

# Introduction

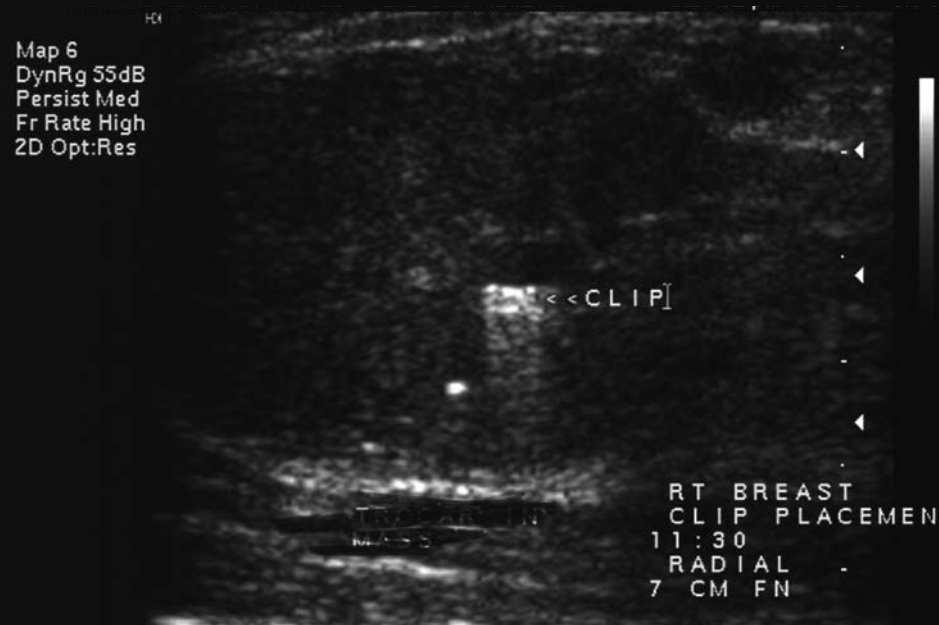
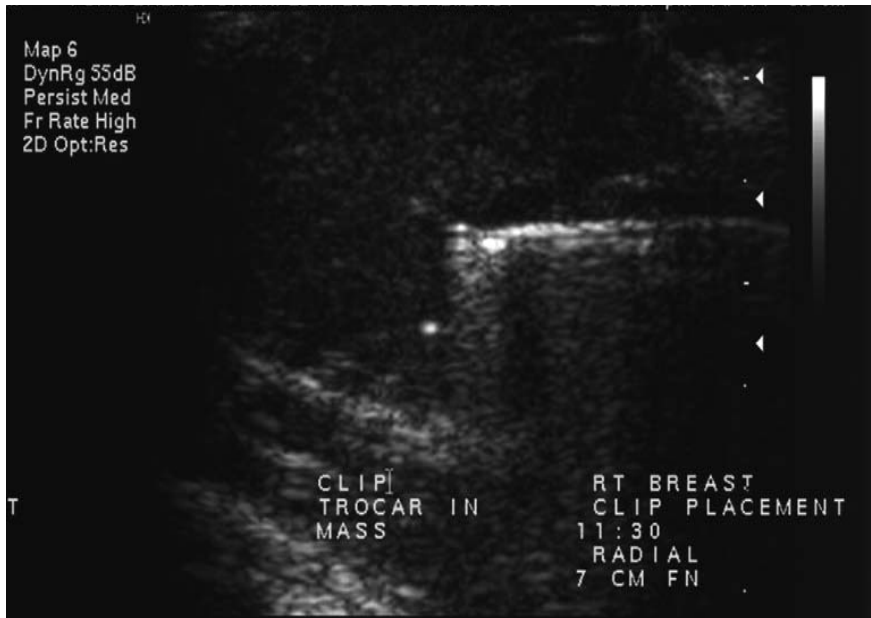
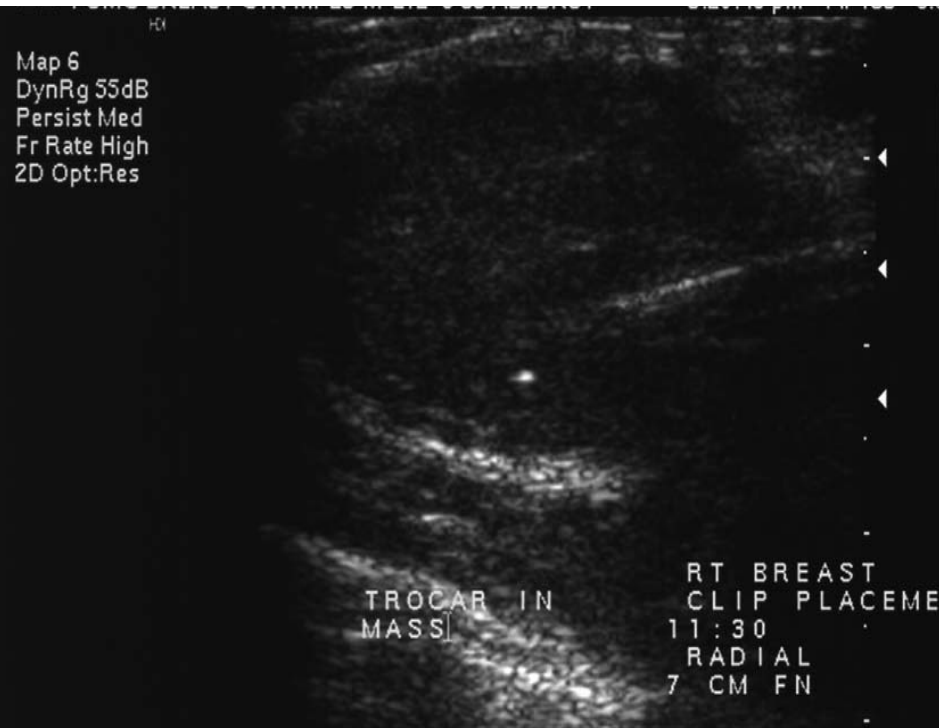
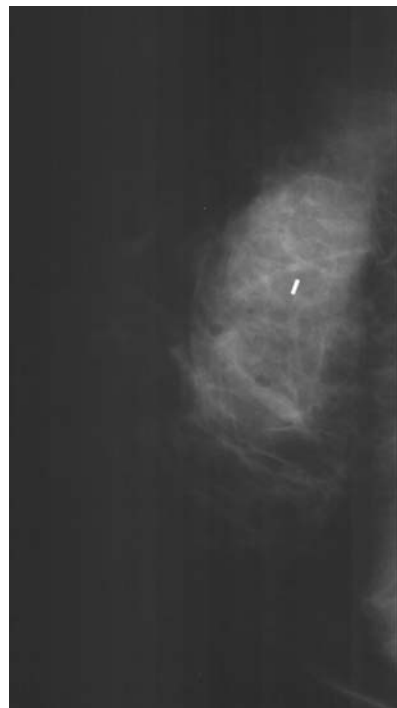
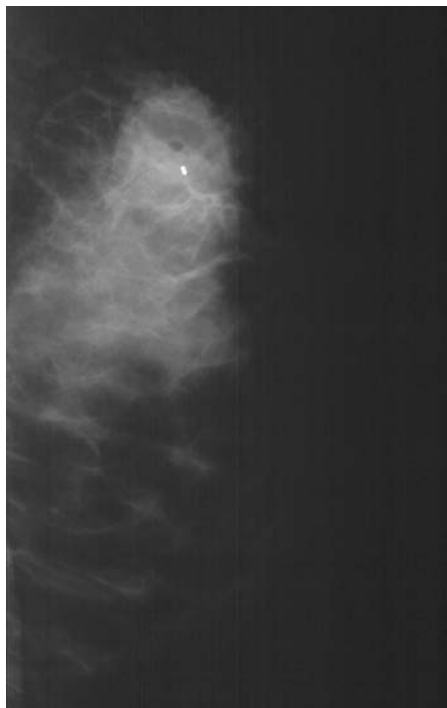
- There is a need for a universal Breast Marker that can be seen easily on mammography, ultrasound, and MRI imaging. Multiple FDA approved soft tissue markers are available to radiologists and surgeons, but all markers do not work for several marking needs.
- The development of a new breast marker (BiomarC, Carbon Medical Technologies) with distinctive characteristics on digital mammography, film screen mammography, ultrasound and MRI was tested on 27 patients with 32 markers placed after ultrasound and stereotactic biopsies.

Images were obtained on:

1. HTL 3000 Ultrasound
2. Senograph GE Digital Mammogram
3. Fischer Stereotactic Biopsy Unit
4. 1.5T Philips MRI with Philips dedicated breast coils
5. 4T images were obtained at CMRR on Oxford Magnet with Varian Console
6. Spectroscopy was obtained using laser technique on 1.5T and 4T Magnets
7. Choline measurements were standardized and obtained on 1.5T and 4.0T magnets

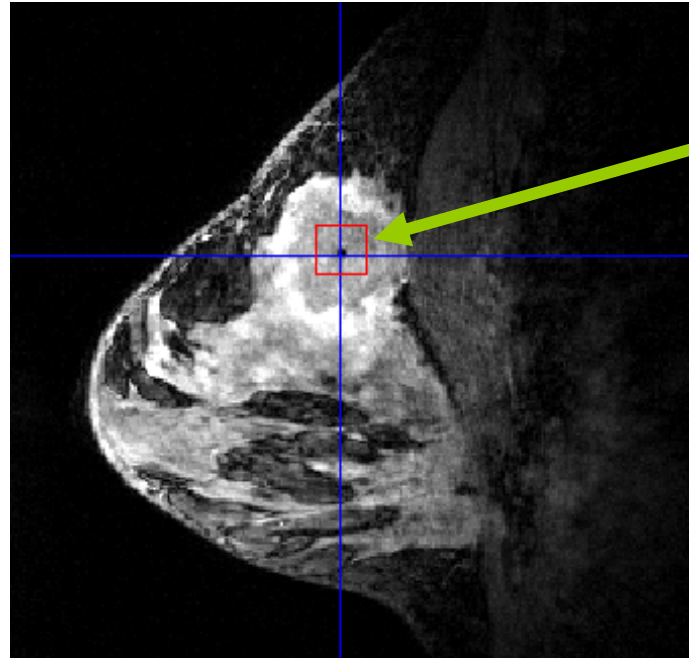
# Case 1

- 47-year old white female with palpable mass upper outer quadrant right breast
- Ultrasound core biopsy which showed invasive ductal carcinoma
- BiomarC placed under ultrasound
- Treatment: Lumpectomy and sentinel node and 1 micro metastasis in lymph node



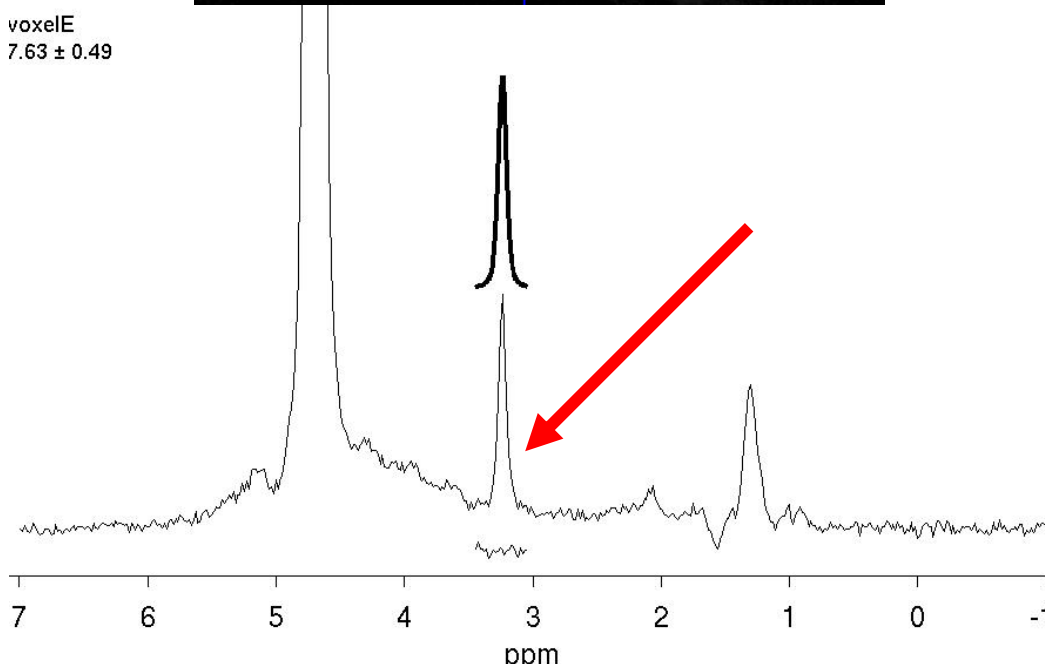
# 4T-MRI

Choline peak is clearly visible over BiomarC

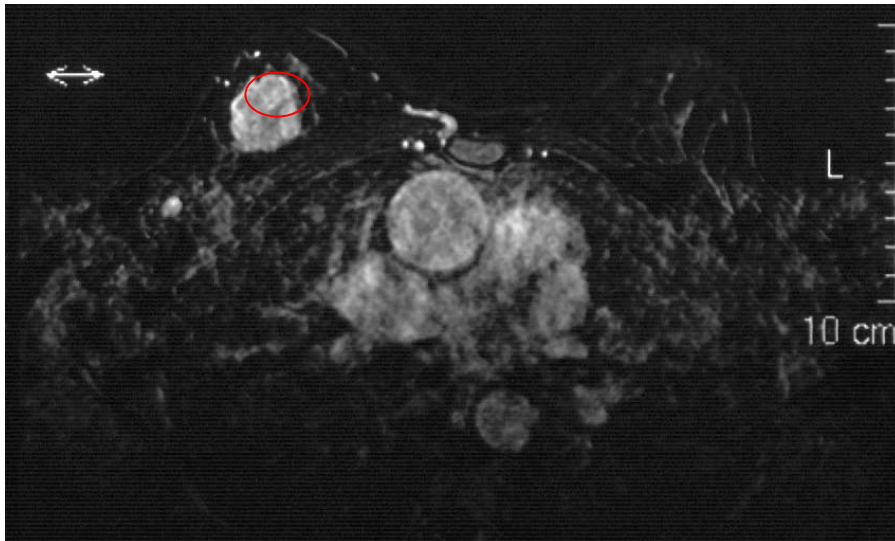
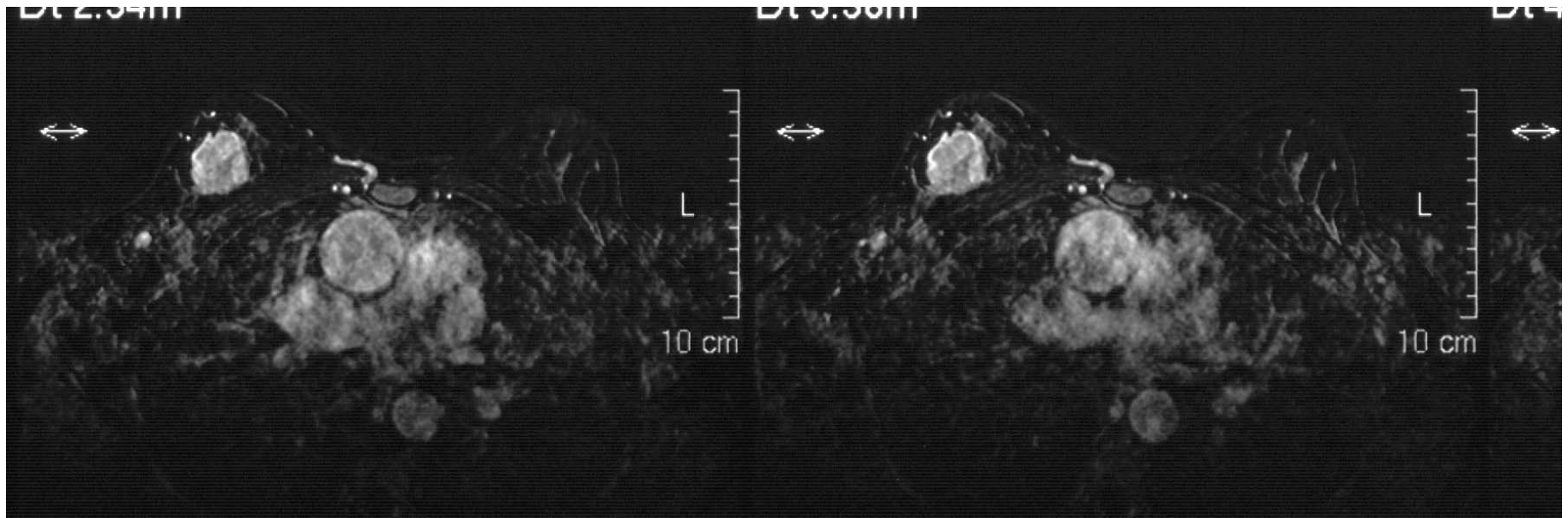


[tCho] = 7.63  
mmol/kg water

voxelE  
7.63 ± 0.49

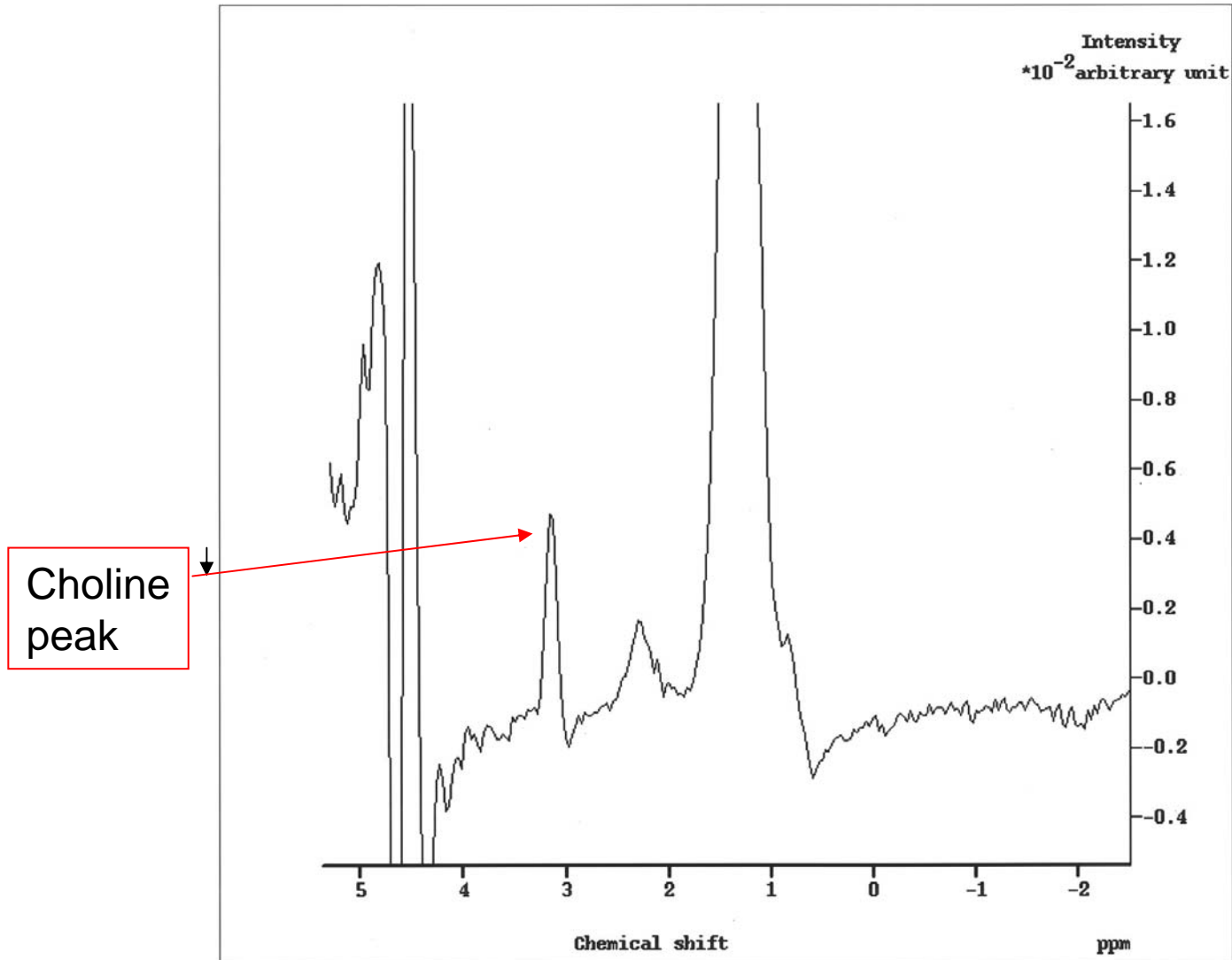


# 1.5T MRI



**BiomarC Placement**

# MRI 1.5T with Spectroscopy

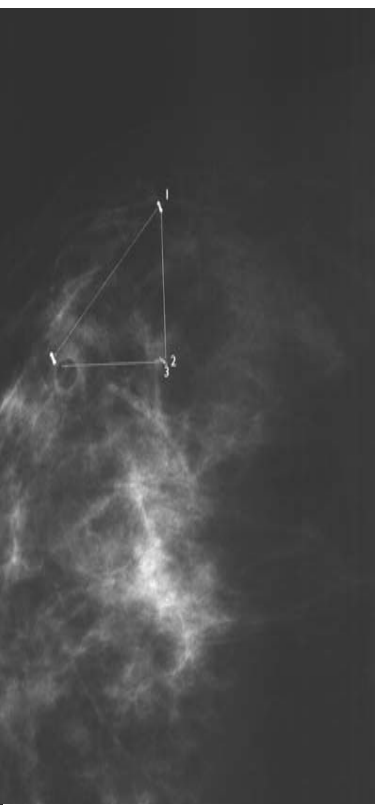
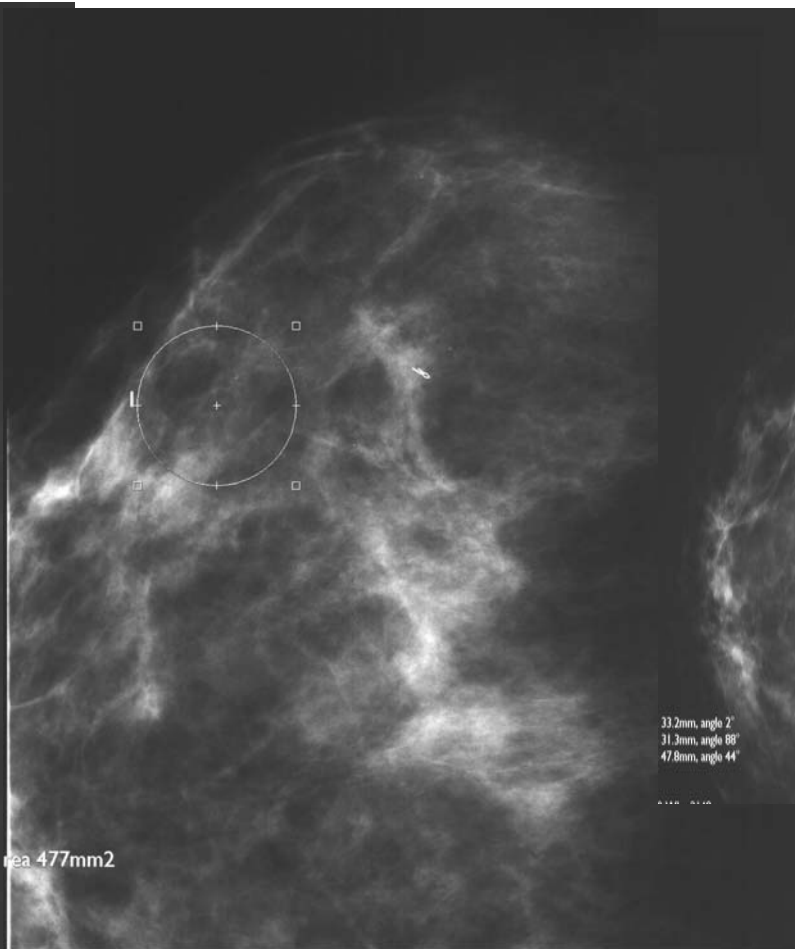
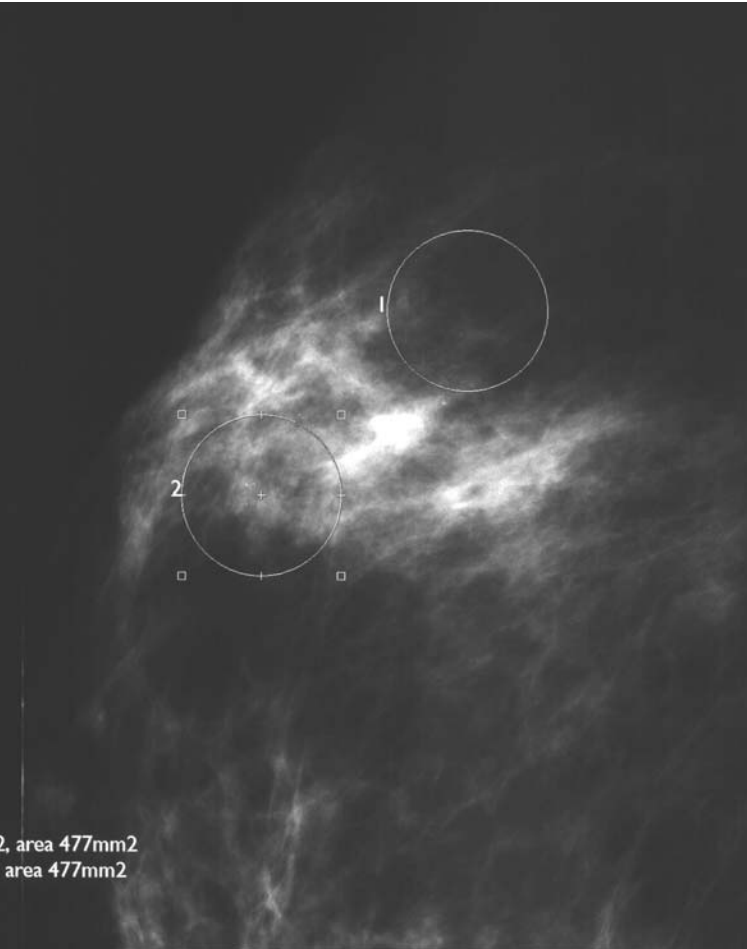




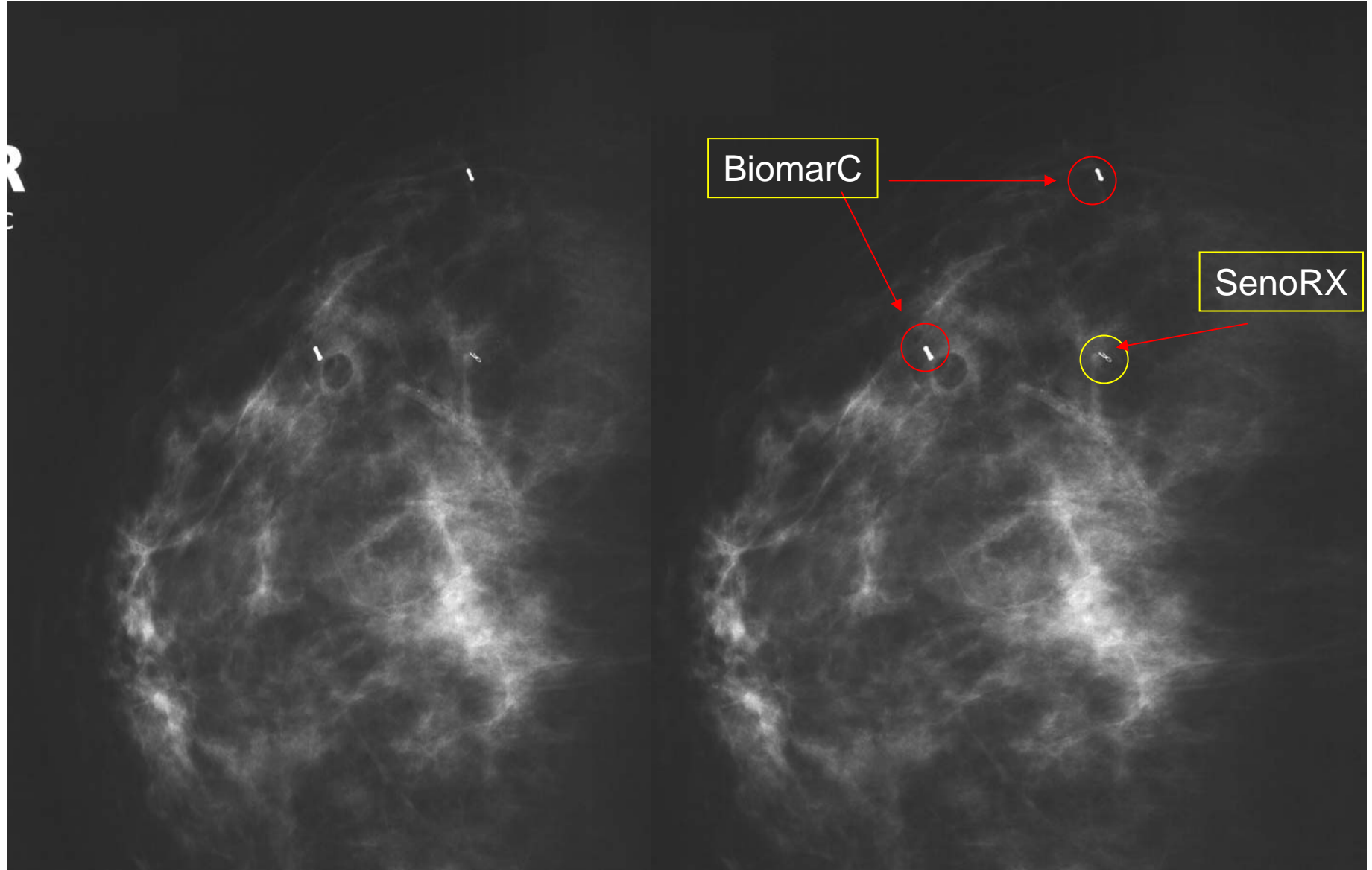
# Case 2

- 45-year-old white female with two areas of abnormal microcalcifications on screening mammogram right breast
- Stereotactic core biopsy showed carcinoma in situ and atypia
- Patient had prior stereotactic biopsy with carcinoma in situ in a third location
- All three areas were marked with unique breast markers

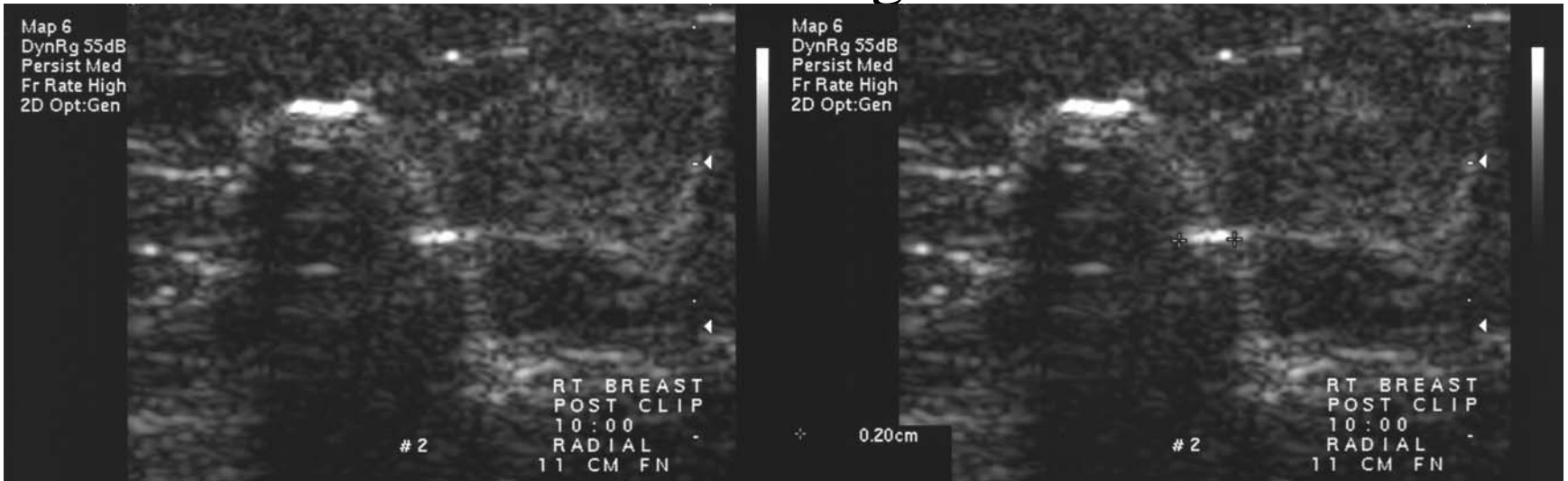
# Case #2



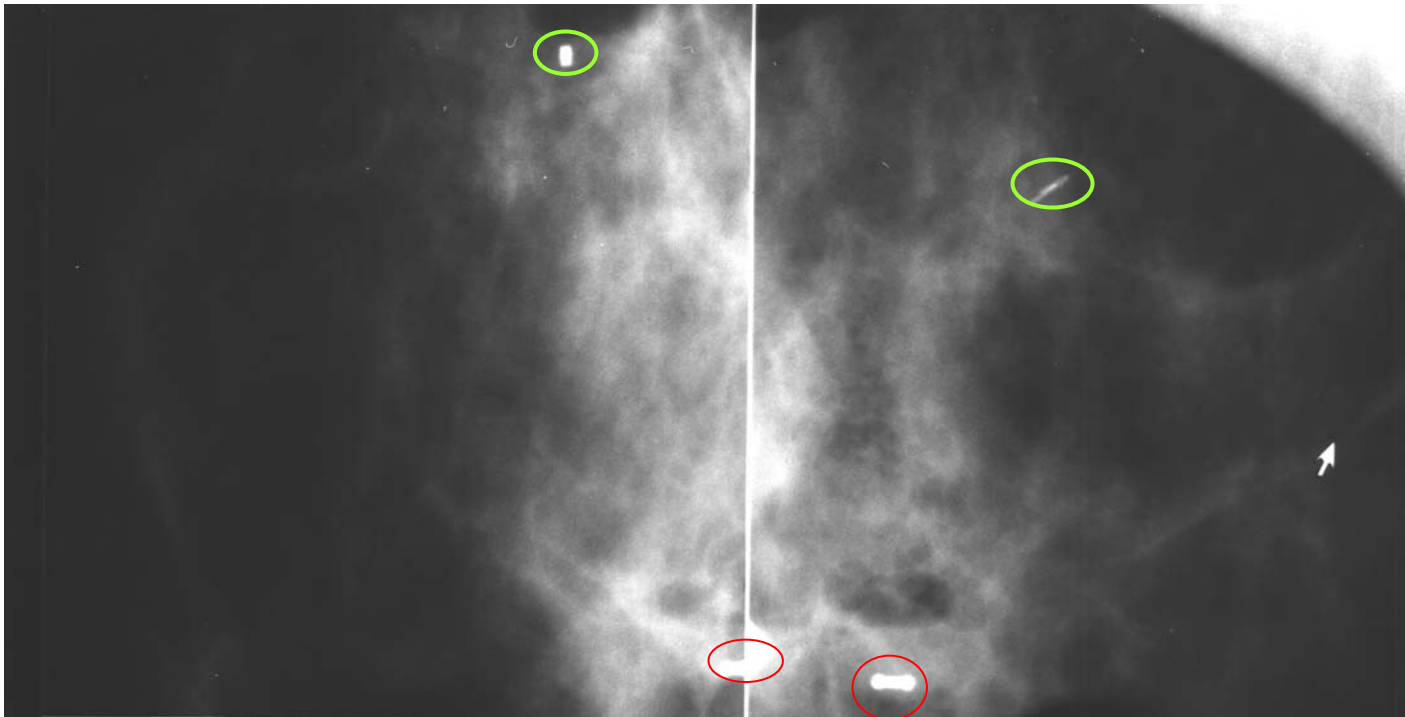
# Case #2



# US Images

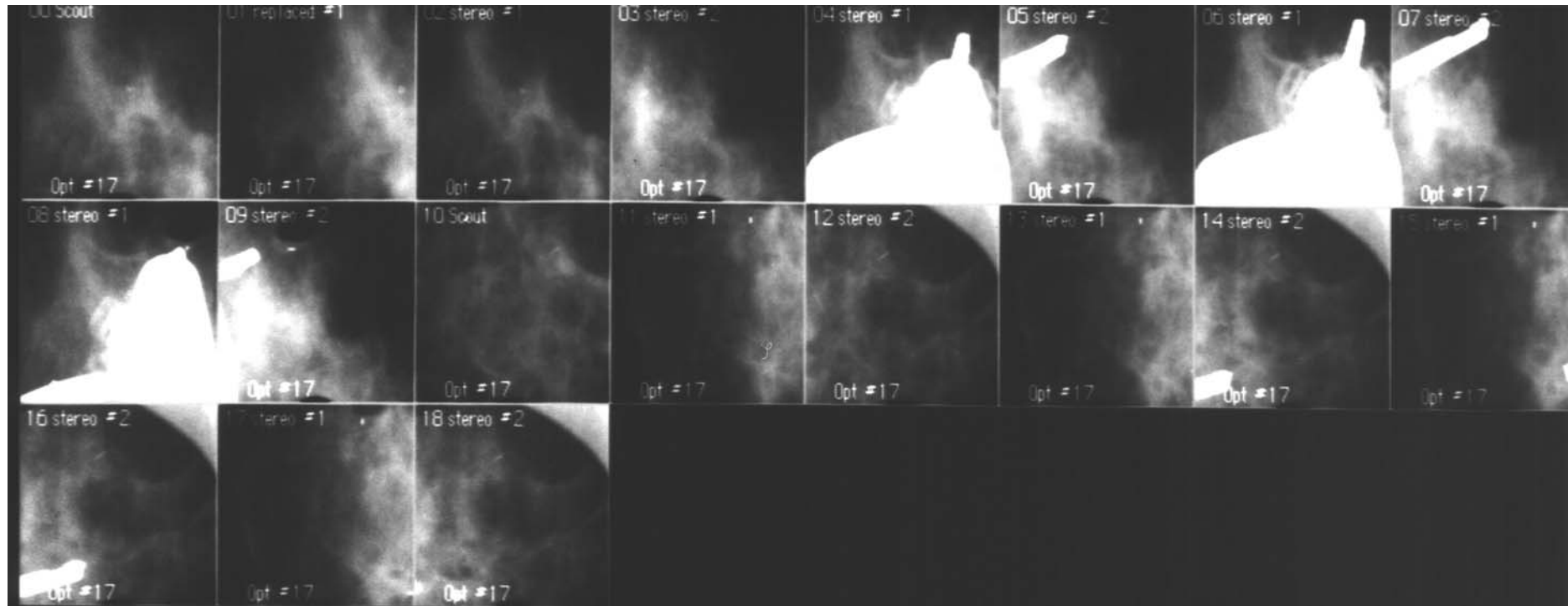


# Stereotactic Images



# Case #2

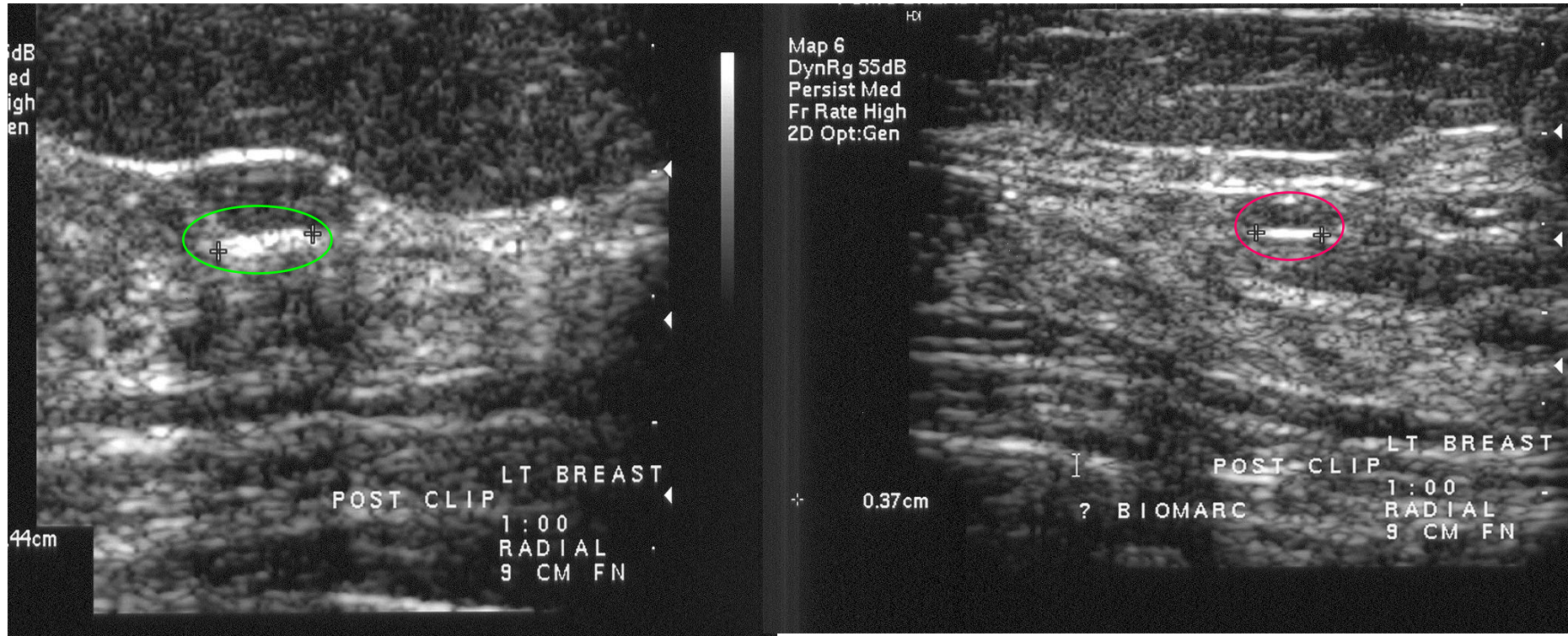
## Stereotactic Marker Placement



# Case #3

- 44-year old female with stereotactic biopsy of left breast with BiomarC placed
- 2<sup>nd</sup> lesion biopsied under ultrasound guidance with a SenoRx S-shaped clip placed
- Pathology showed both areas were FCC

# Case #3



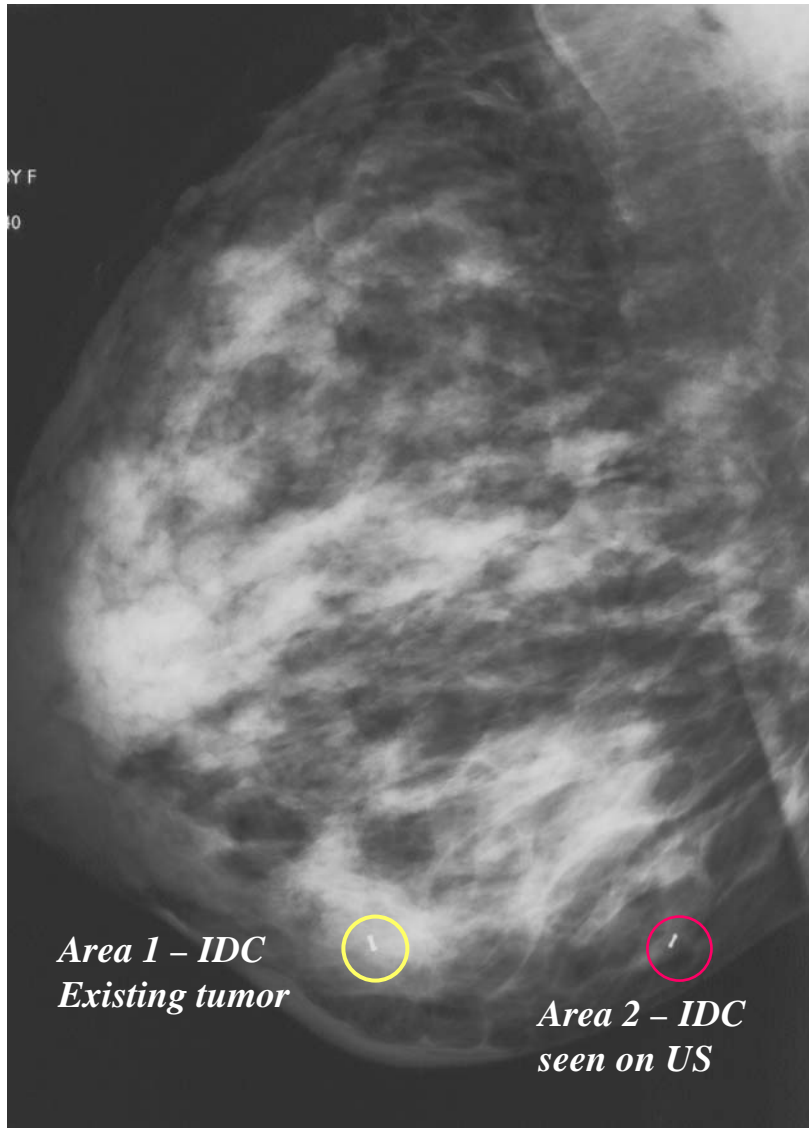
SenoRx Ultra Core

BiomarC

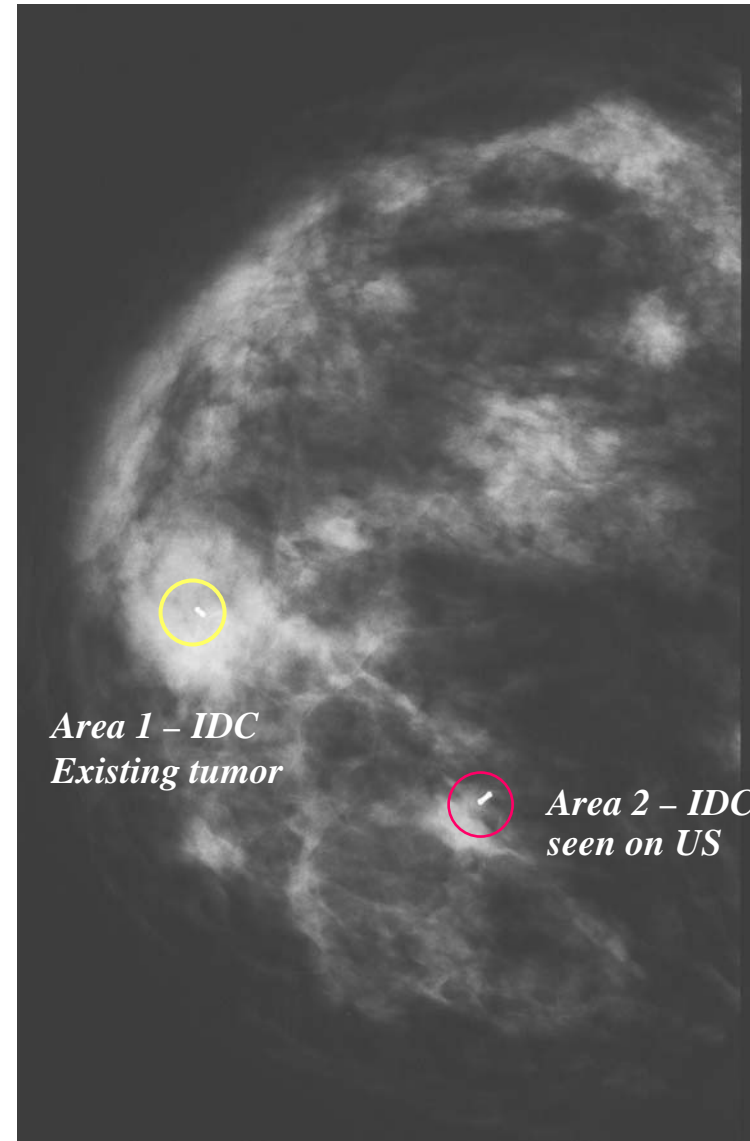
# Case #4

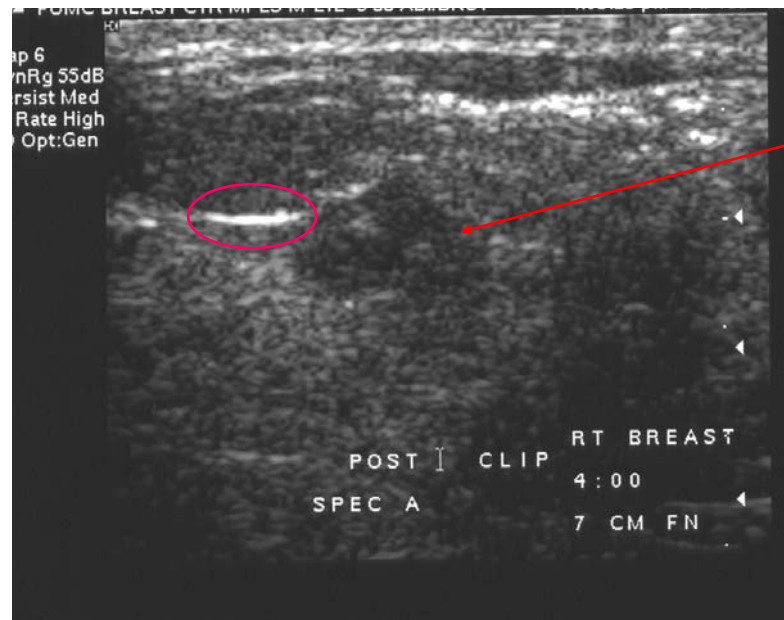
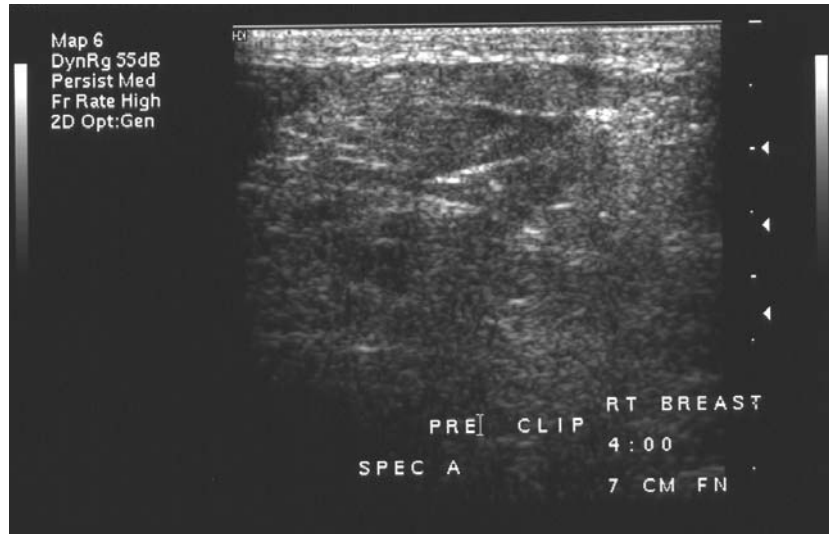
- 38-year old white female presented with existing IDC with outside biopsy
- Second lesion in lymph node was identified on ultrasound exam in the right breast
- BiomarC was placed in existing tumor under US guidance
- 2<sup>nd</sup> BiomarC was placed in second tumor under US guidance identified at 4 o'clock
- Lymph node in right axilla was biopsied and also positive for IDC. Lymph node not marked with marker
- Pathology showed two areas of IDC with positive lymph node in the right breast





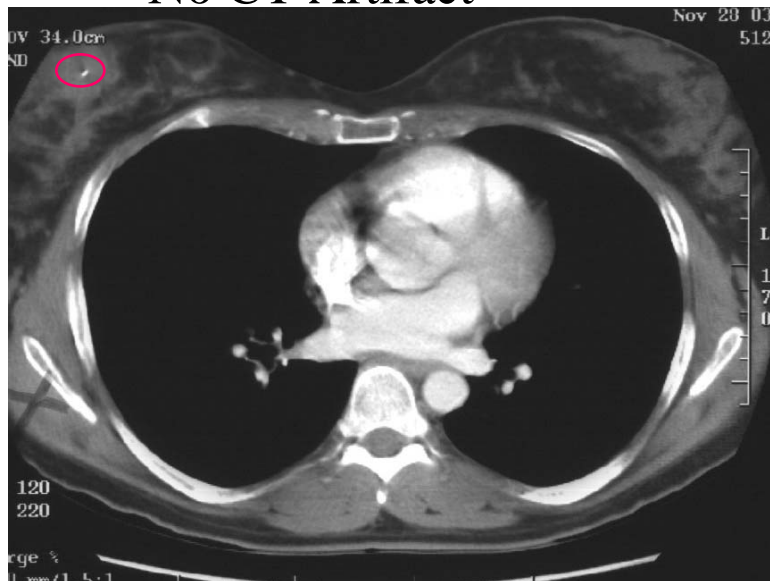
## **BiomarC**



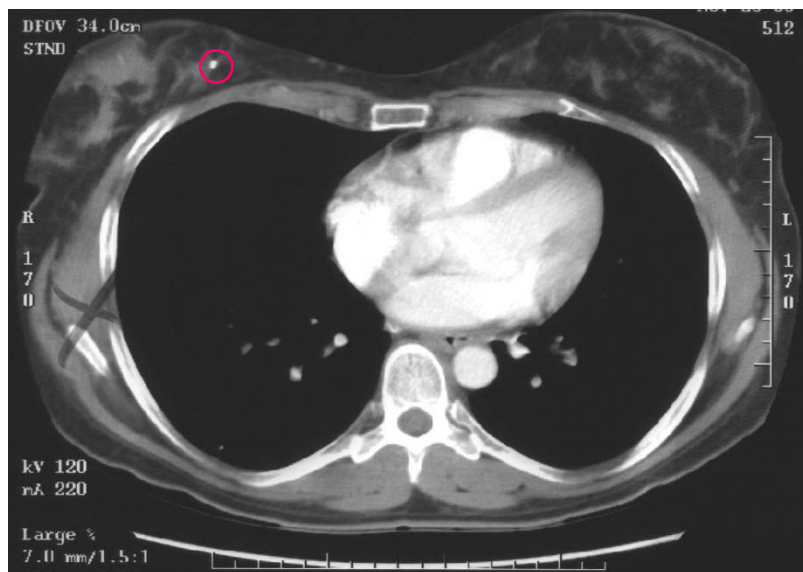
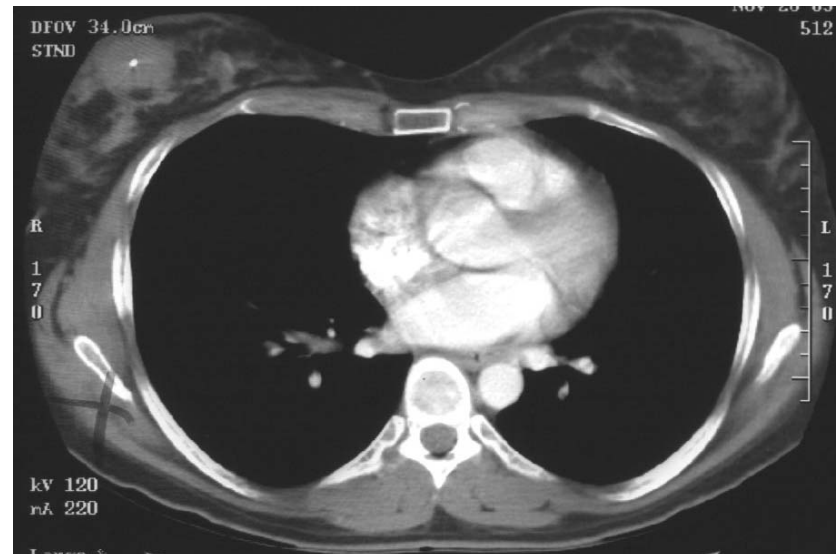


BiomarC

BiomarC on CT within  
Breast IDC mass  
No CT Artifact

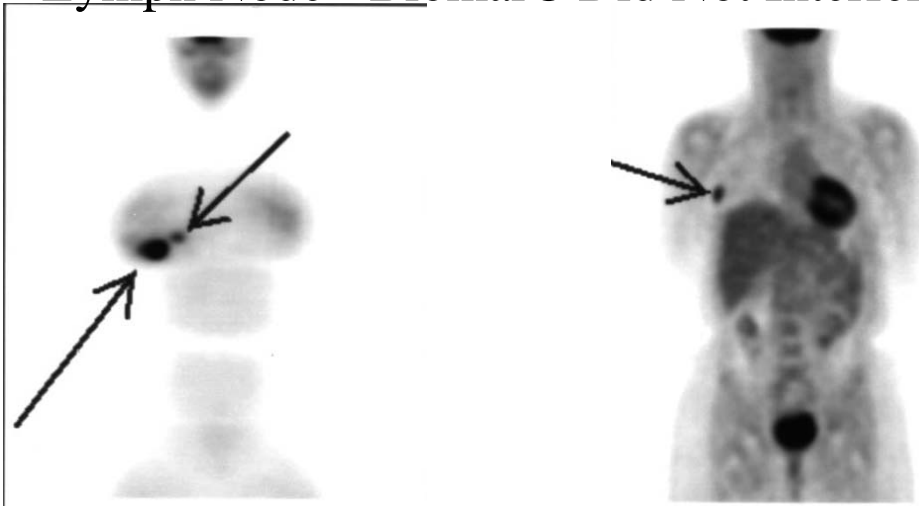


BiomarC in Right Breast Mass

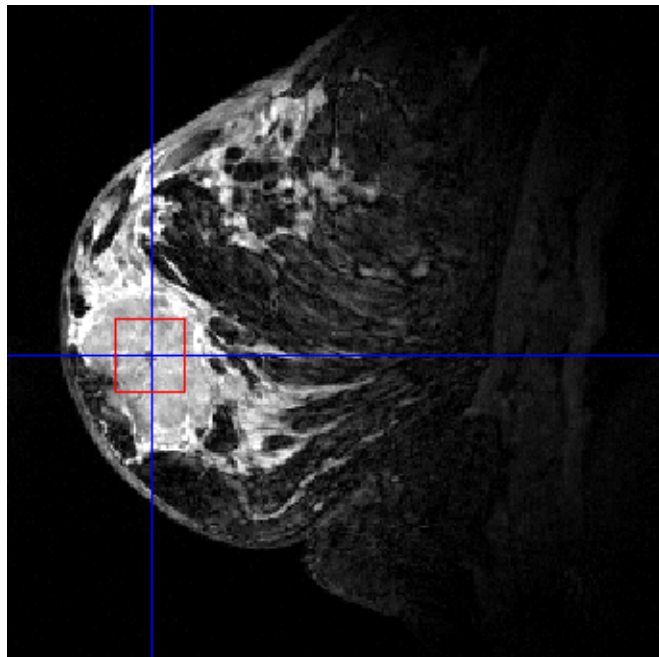


Second IDC Lesion in Right Breast  
Medially  
with BiomarC

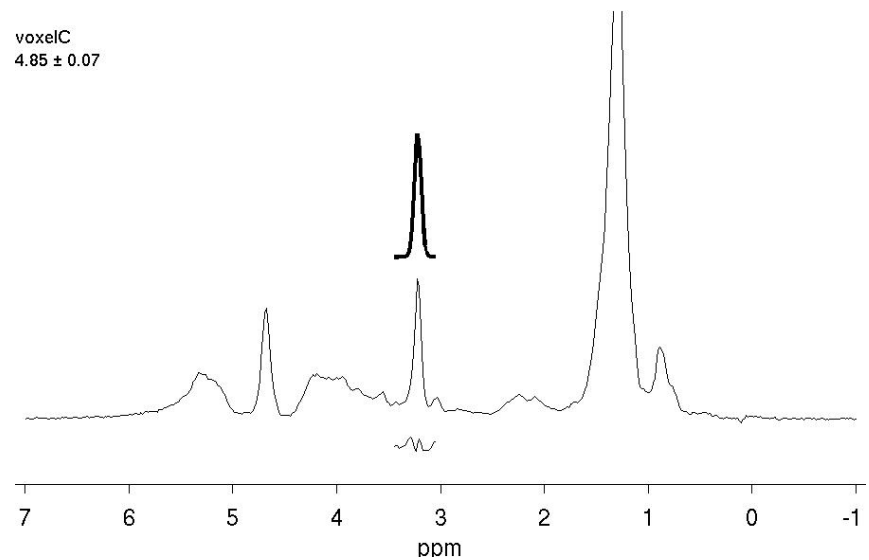
# PET Scan Showing Two Areas of IDC Right Breast and Positive Right Axillary Lymph Node - BiomarC Did Not Interfere With PET Scan



BiomarC in center of mass  
does not interfere with spectroscopy



Spectrum taken right over the RM with minimal error  
[tCho] =  $4.85 \pm 0.07$

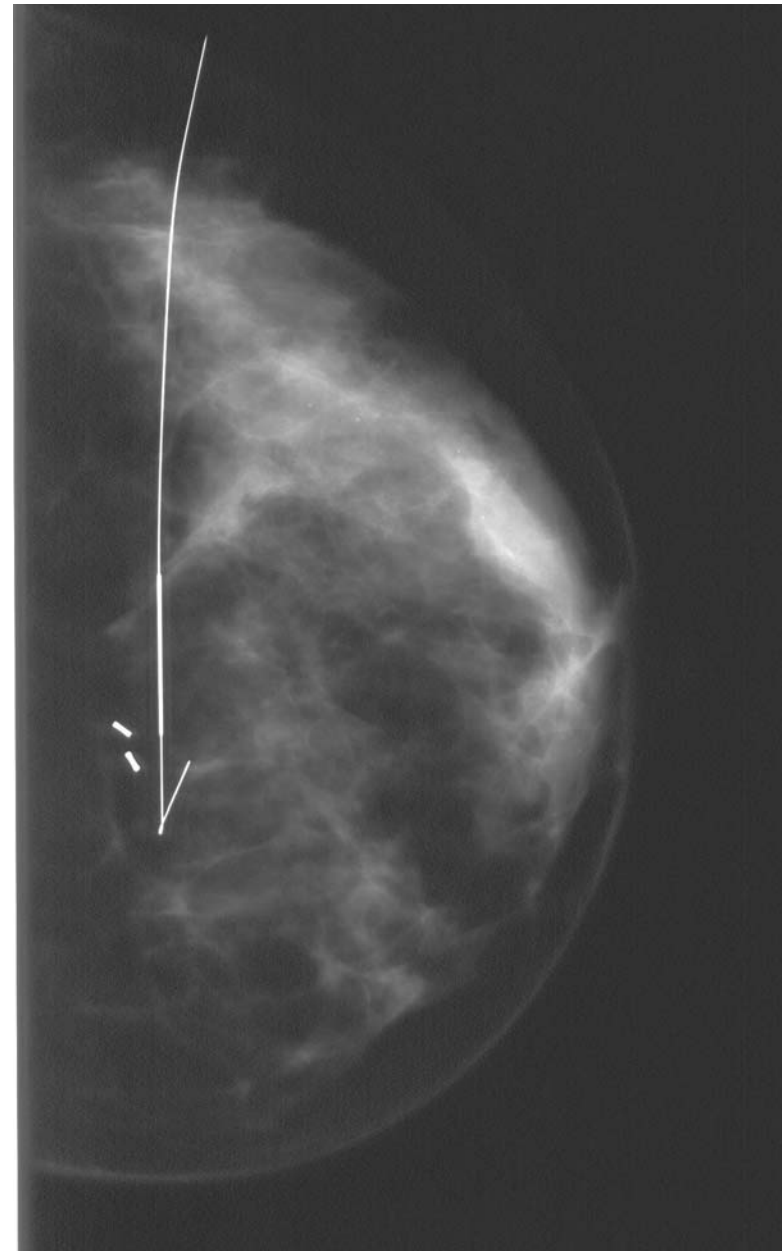
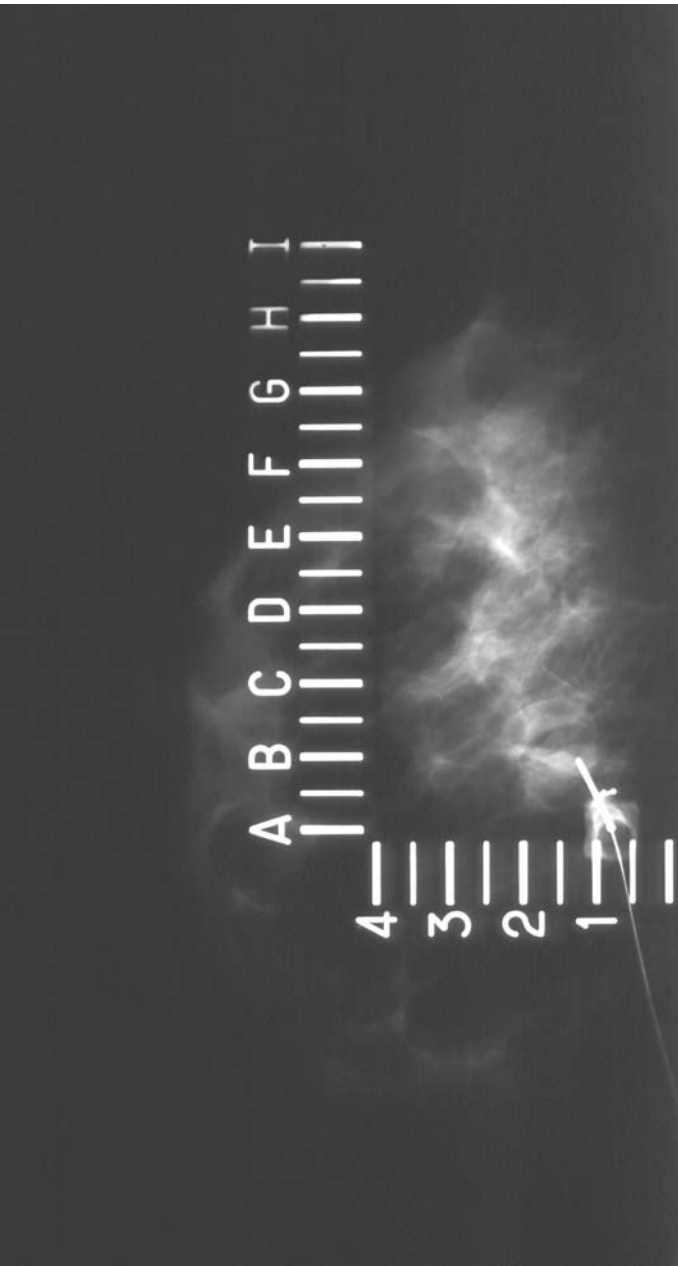


# Case #5

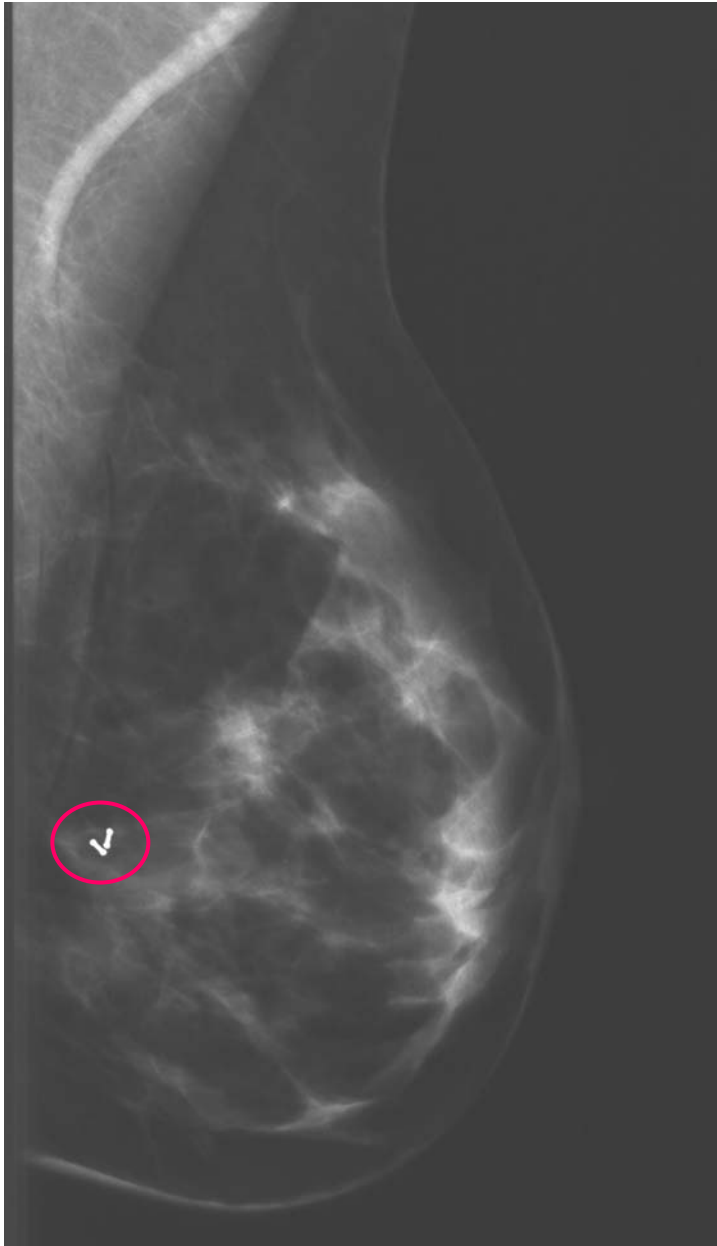
- 43-year old white female has two sisters with breast cancer
- Had screening MRI with one area of increased gadolinium enhancement
- 2 BiomarC markers were placed at the site of enhancement and an open biopsy was done with wire localization
- Biopsy showed FCC

# Case #5

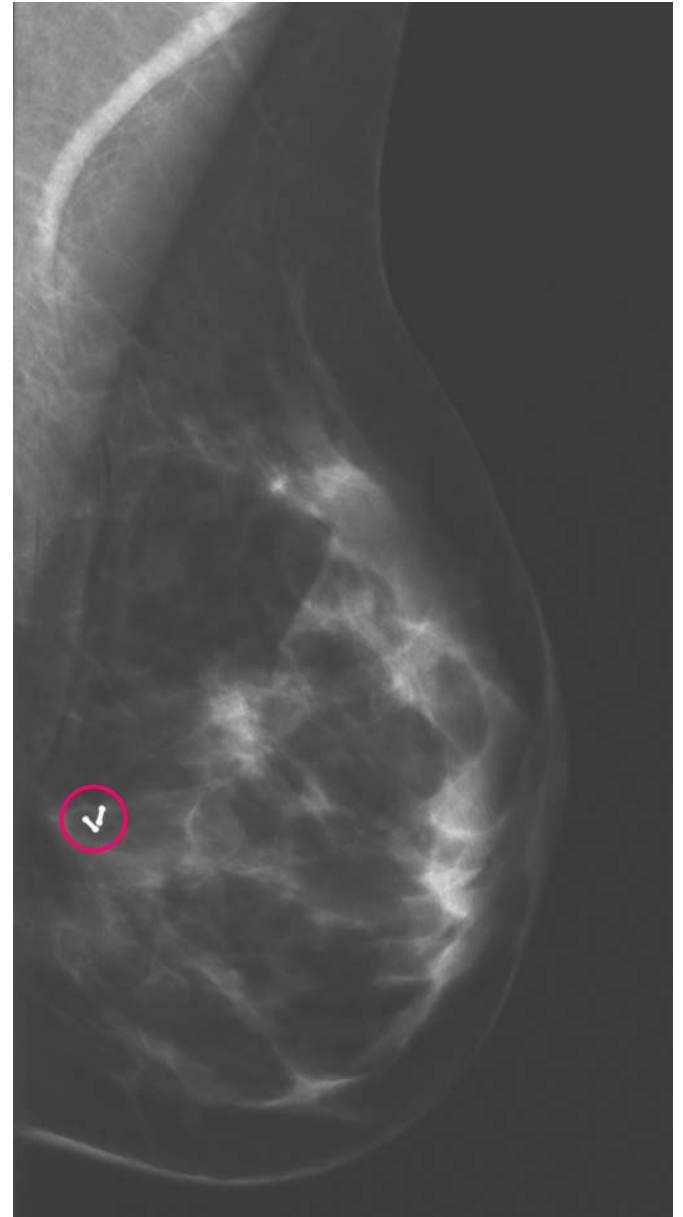
7 cm Kopans wire  
localization done  
with Digital  
Mammography  
using BiomarC  
markers placed  
under MRI



# Case #5



2 BiomarC  
markers placed  
under MRI  
Guidance with  
Titanium 120  
mm Trochar

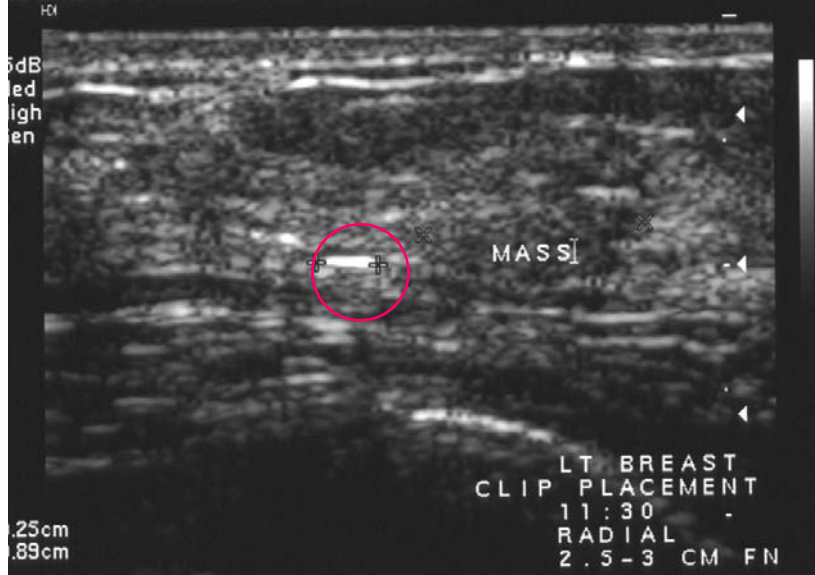
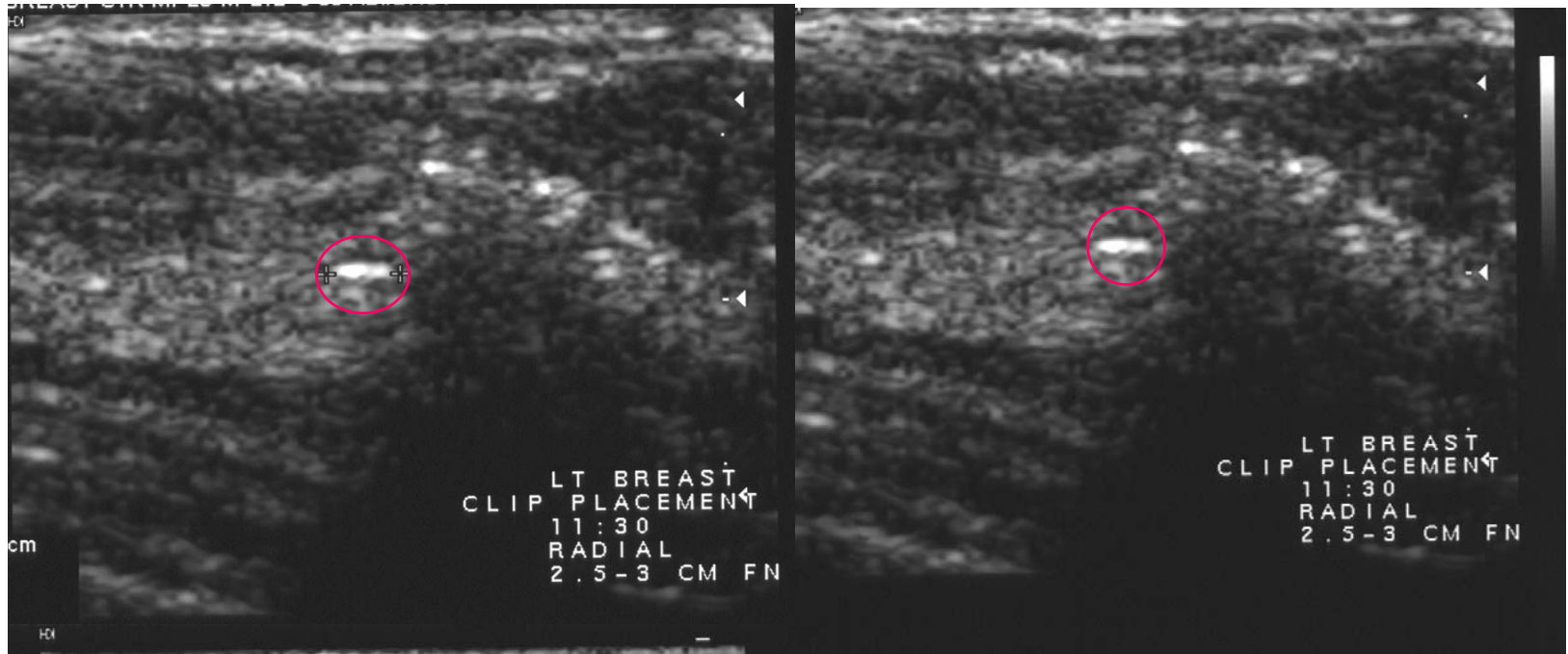


# Case #6

- 32-year old white female with palpable mass left breast
- US showed hypoechoic mass at 11:30 o'clock 3cm from nipple
- US Bx completed with BiomarC placed under US guidance
- Pathology showed benign fibrocystic changes
- BiomarC placed under US guidance and was well visualized on US and mammography



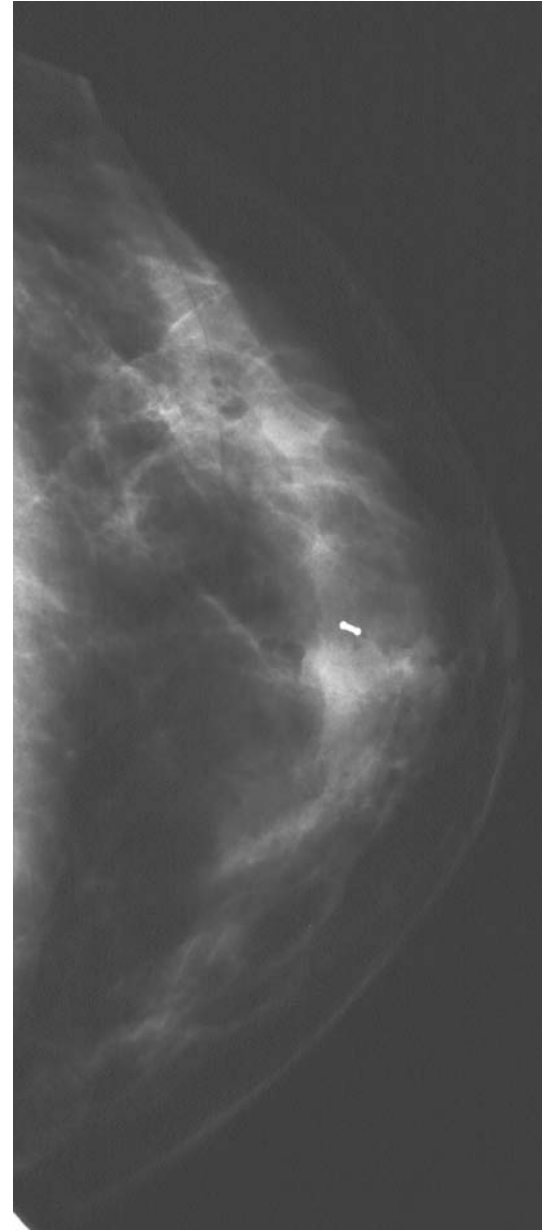
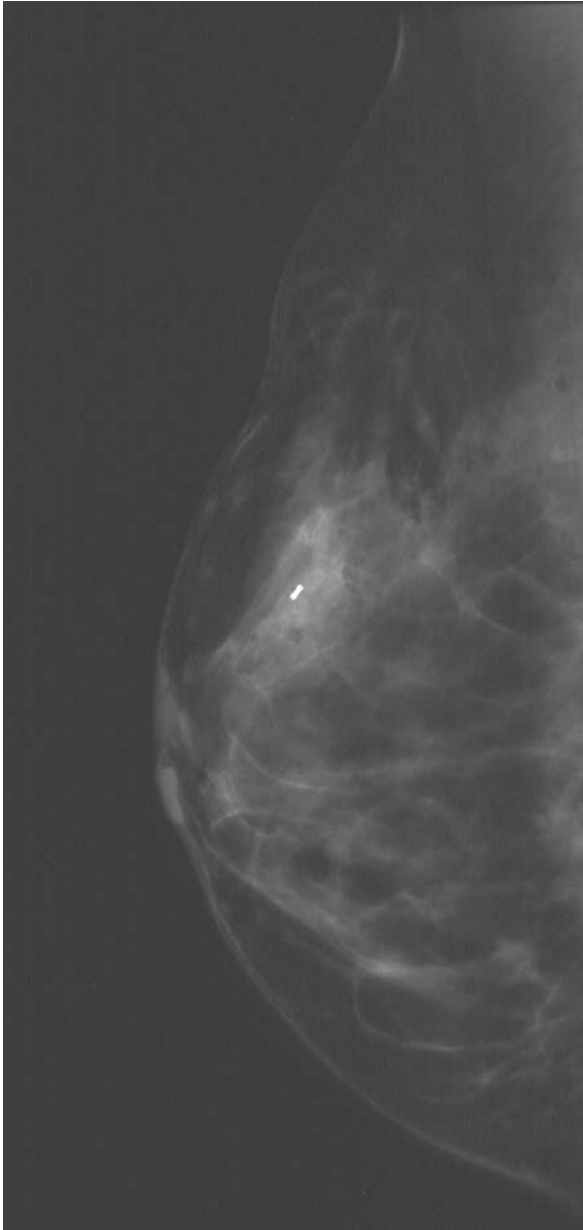
# Case #6



BiomarC placed under US guidance with good visualization

# Case #6

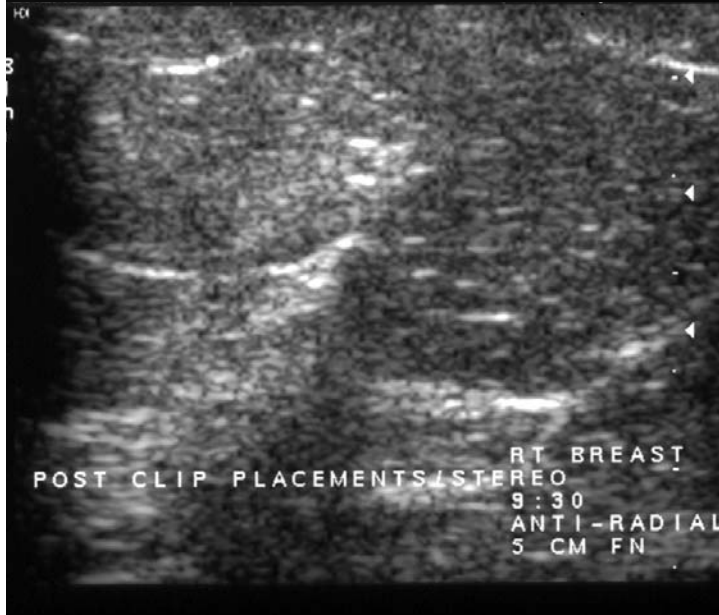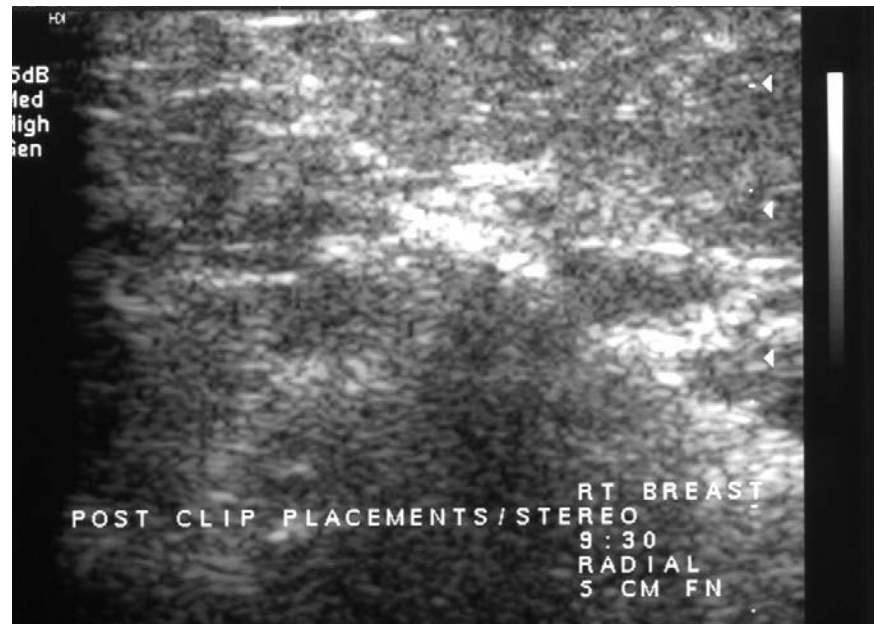
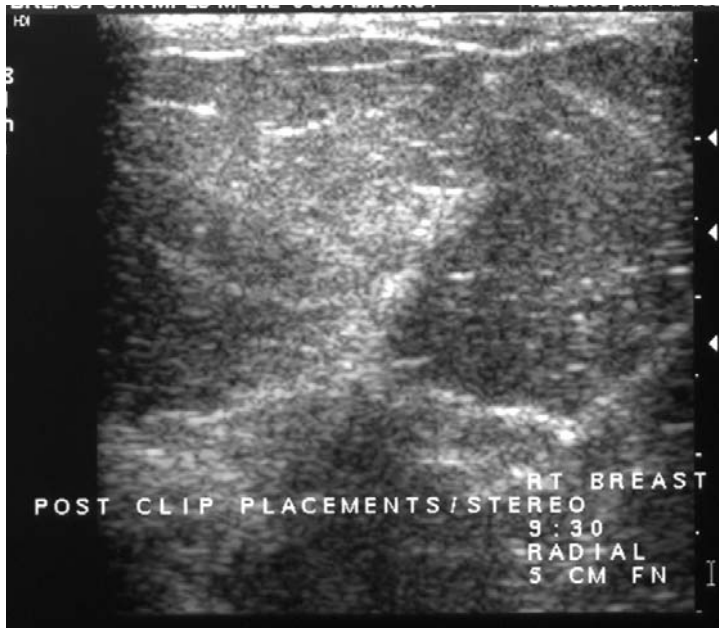BiomarC markers  
under Digital  
mammography



# Case #7

- 50-year old white female with two areas of abnormal microcalcifications in right breast on screening mammogram
- Both areas were biopsied using stereotactic vacuum assisted 11-gauge biopsy needle
- Superior area was marked with BiomarC using wet technique through hollow catheter
- 2<sup>nd</sup> biopsy area was marked with a new SenoRx titanium marker
- Pathology both areas was FCC

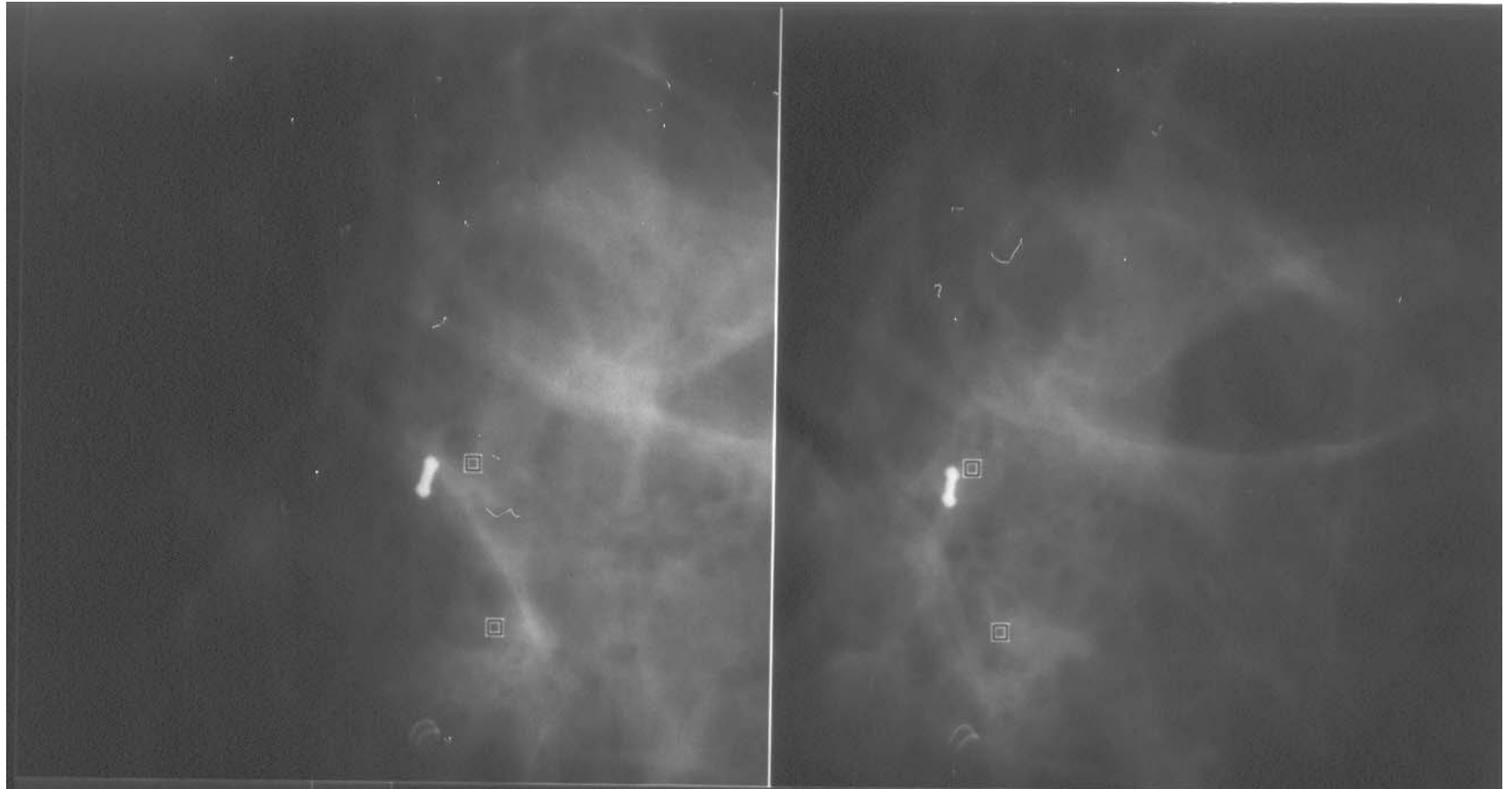
# Case #7



- Neither BiomarC or SenoRx titanium clip could be seen on US after stereotactic placement
- Both clips were placed in fatty breast tissue

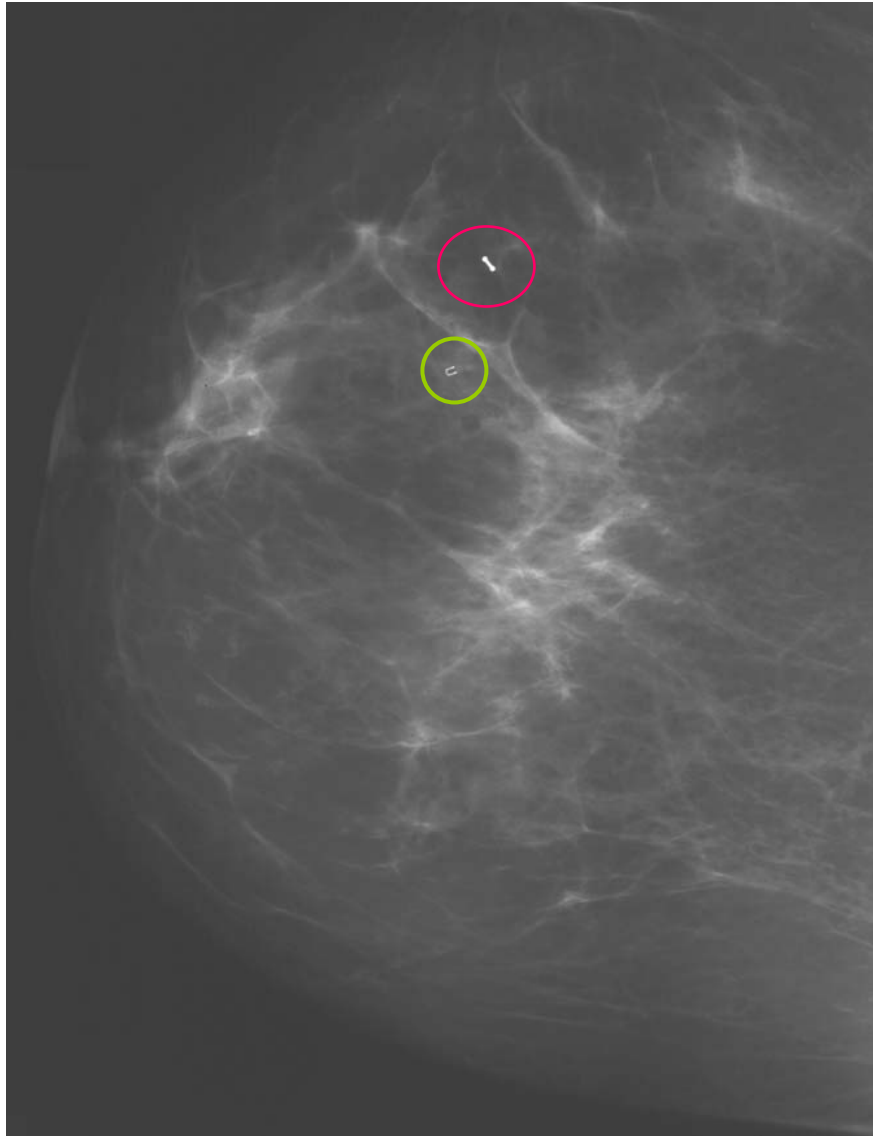
# Case #7

Stereotactic Placement of BiomarC seen under  
Stereotactic Imaging (Fischer Imaging Biopsy Table)

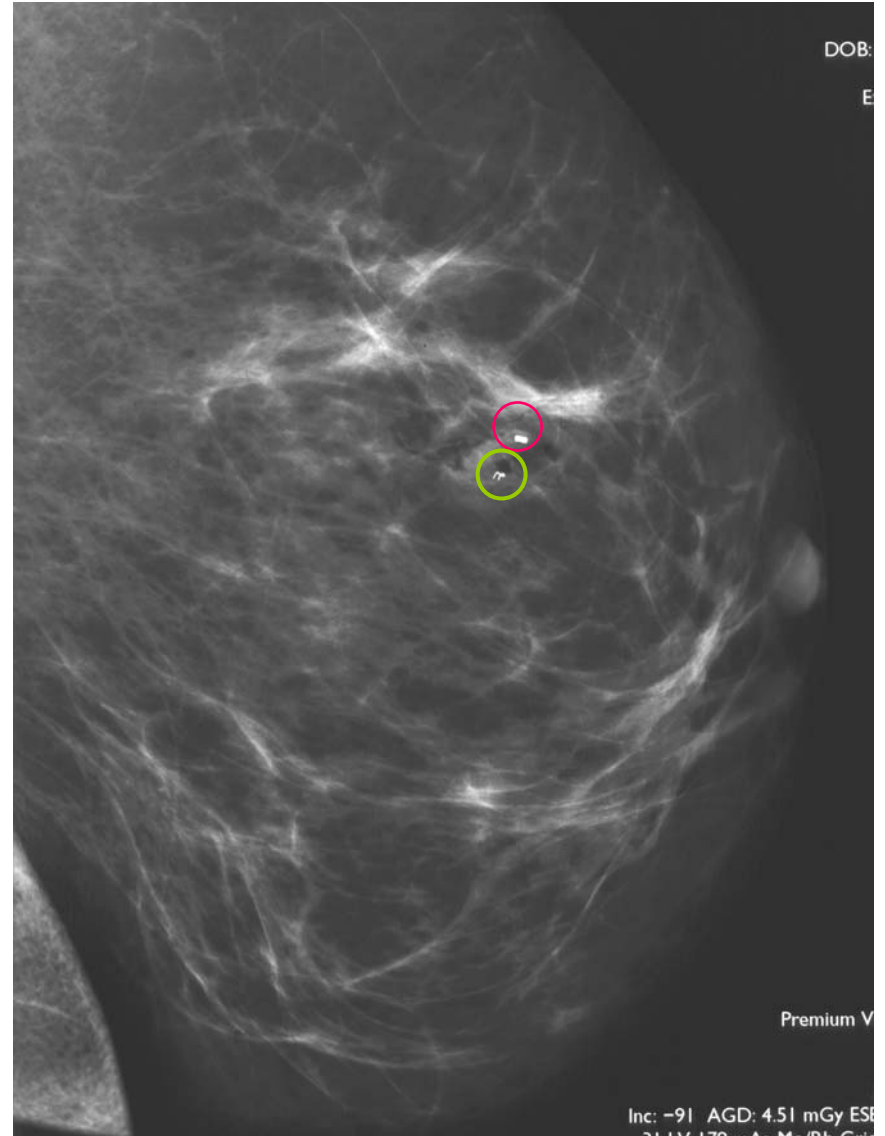


# Case #7

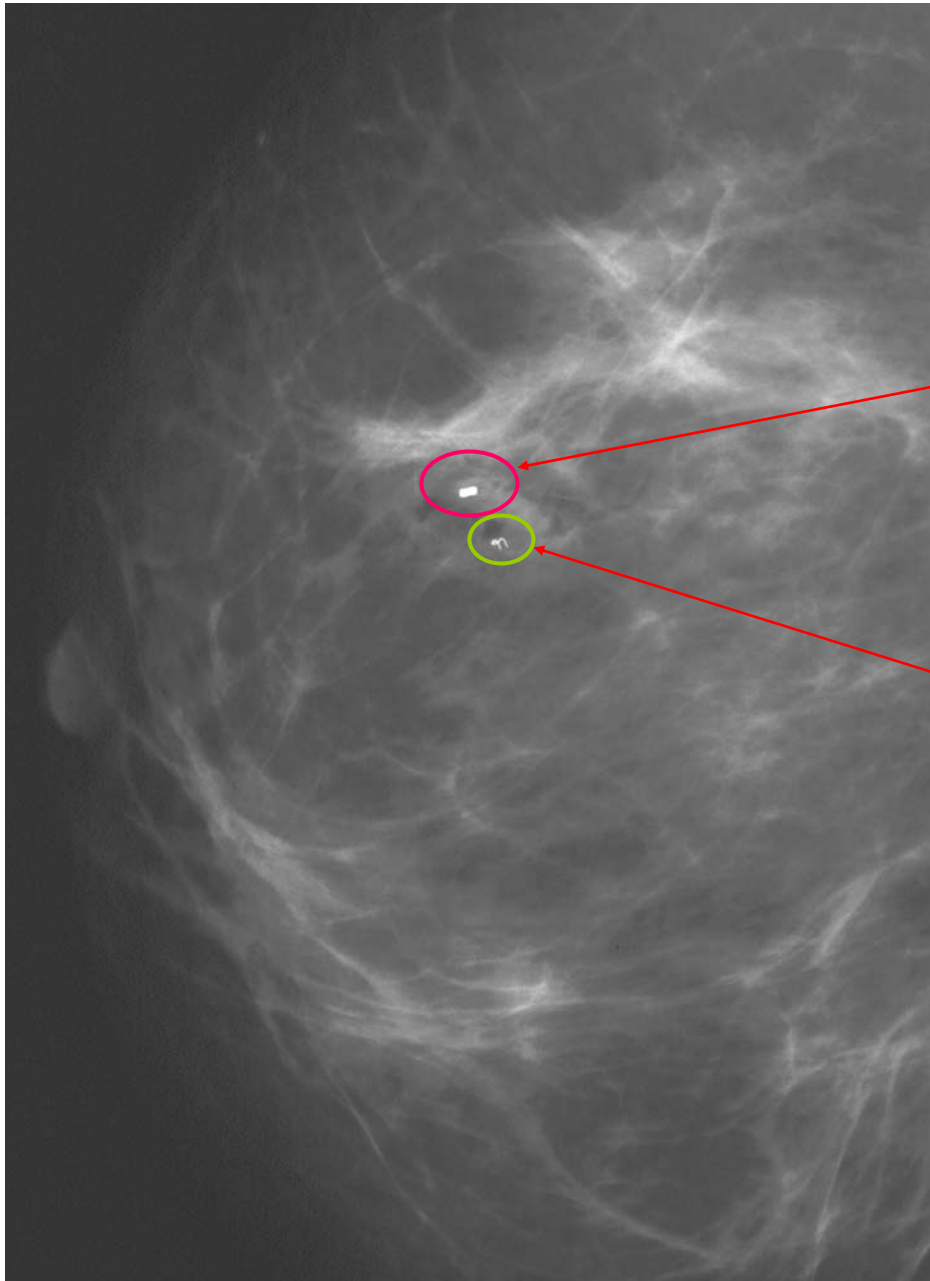
BiomarC markers



SenoRx markers



# Case #7



BiomarC

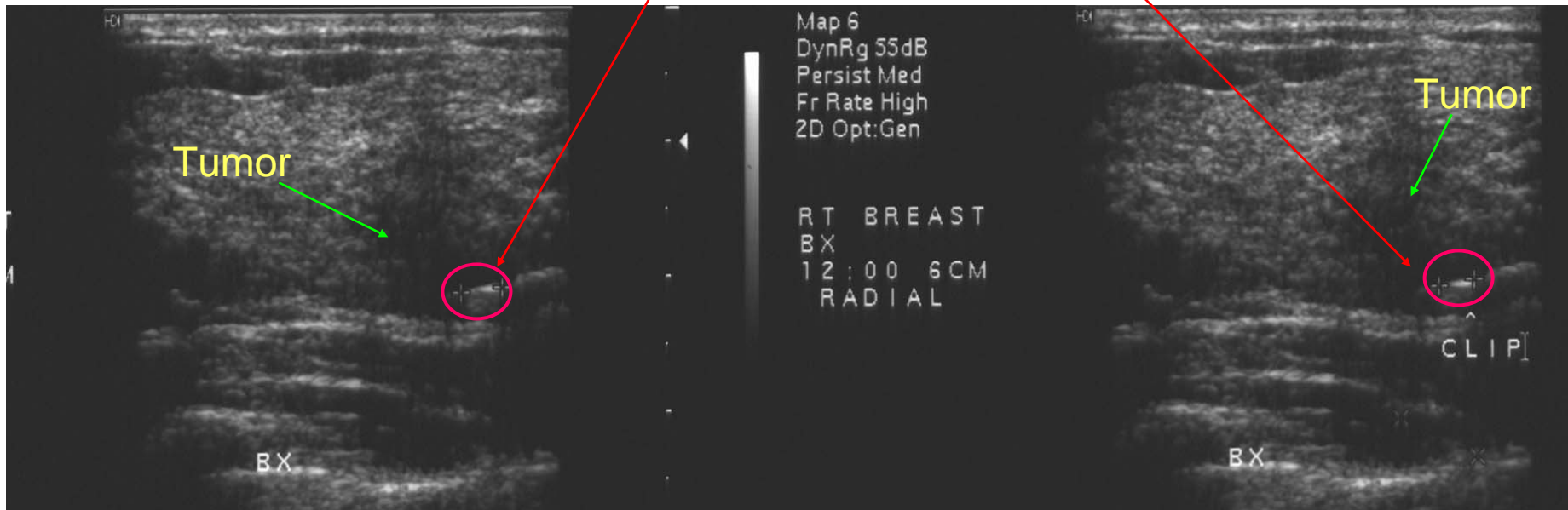
SenoRx Titanium

# Case #8

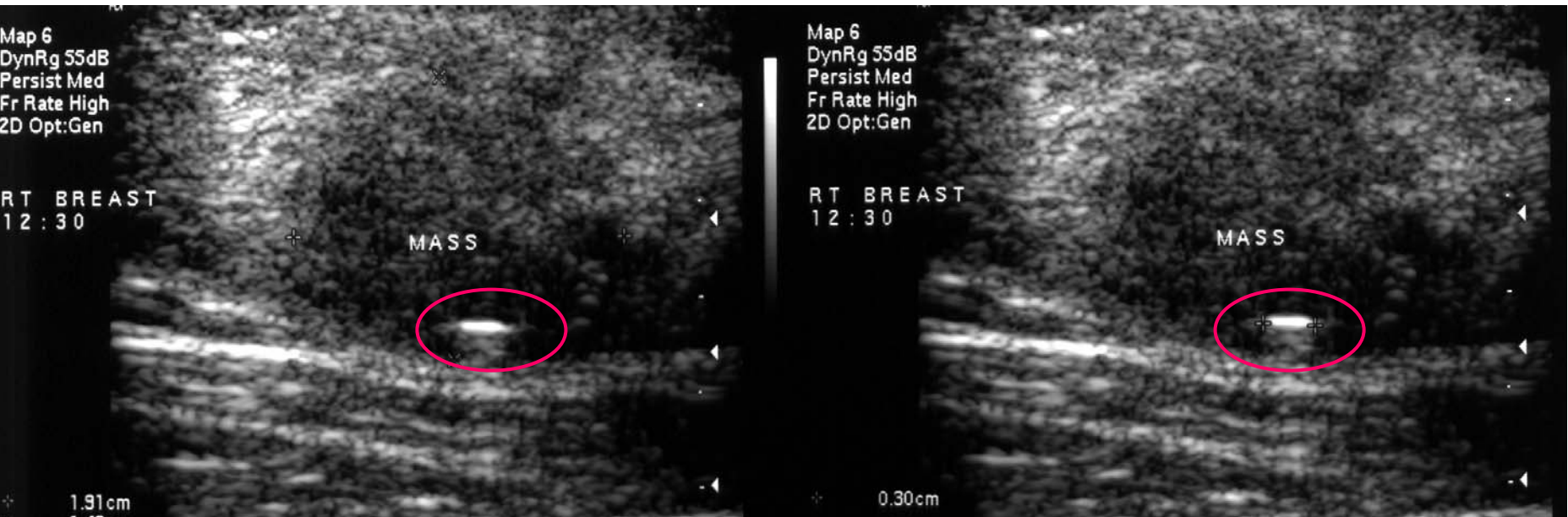
- 39-year old white female with palpable lump right breast at 12 o'clock
- US core Bx 14-gauge was done with placement of BiomarC under ultrasound guidance
- Digital mammography showed marker to be in good position
- US taken 7-days later showed the BiomarC well visualized under US
- Pathology showed IDC



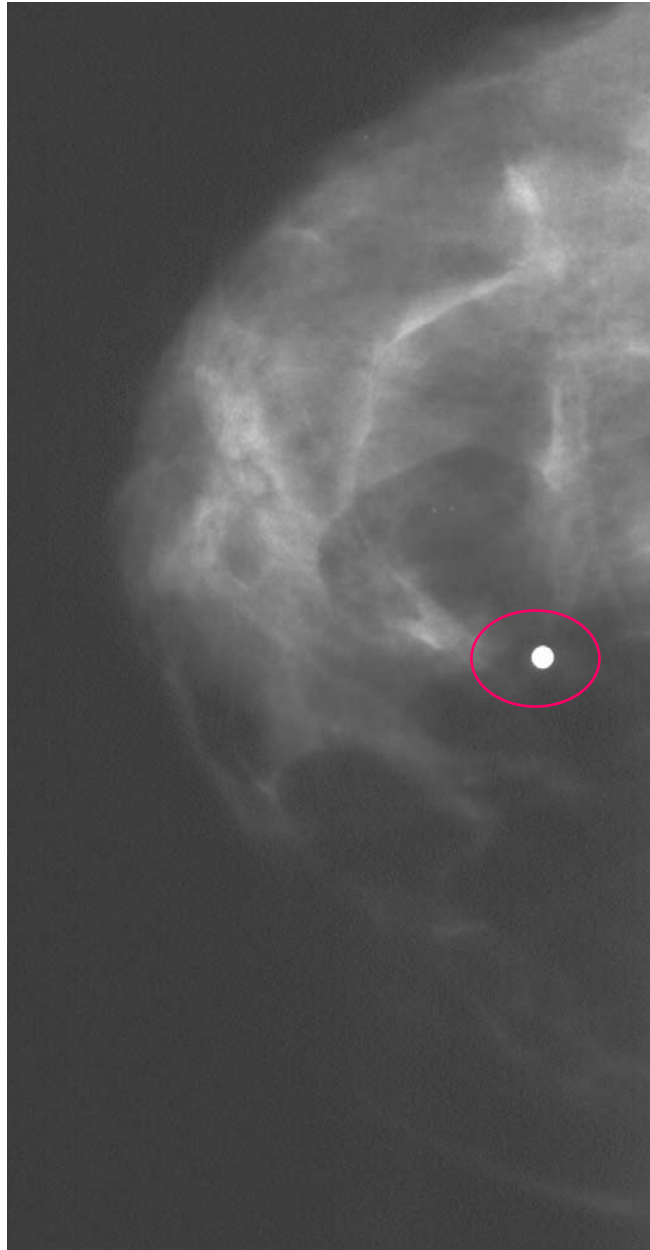
# BiomarC placed under US Guidance



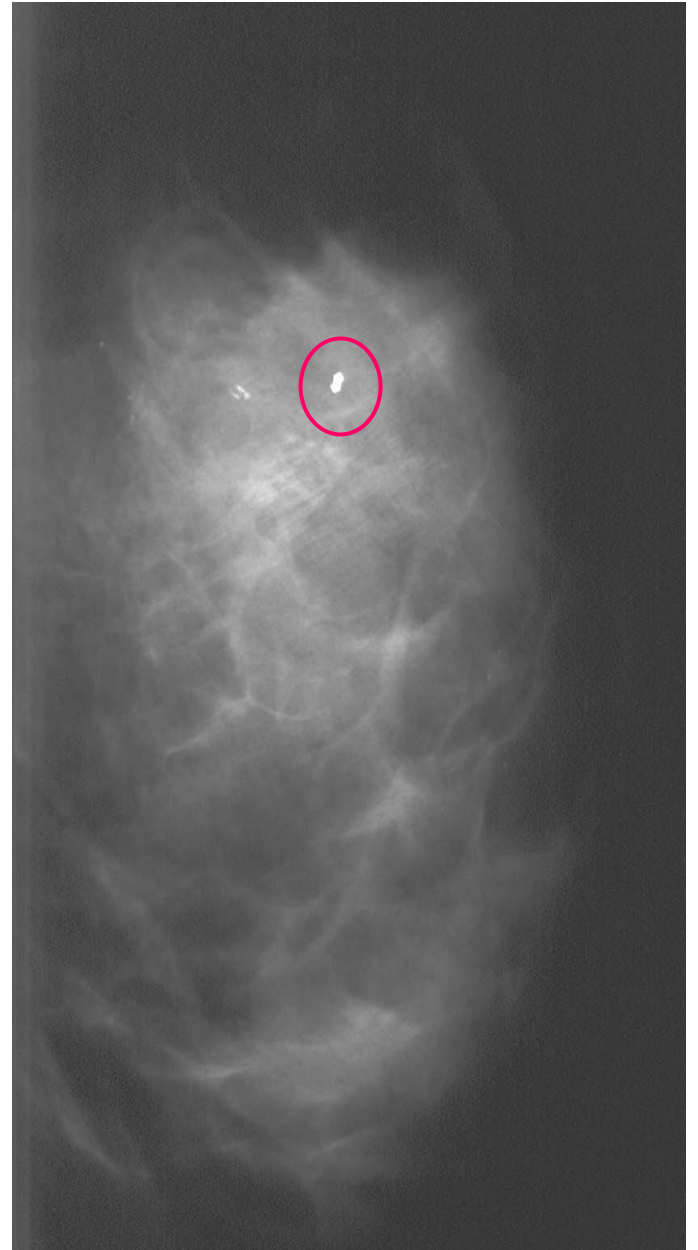
Good visualization of BiomarC 7-days after placement under US



# Case #8



BiomarC

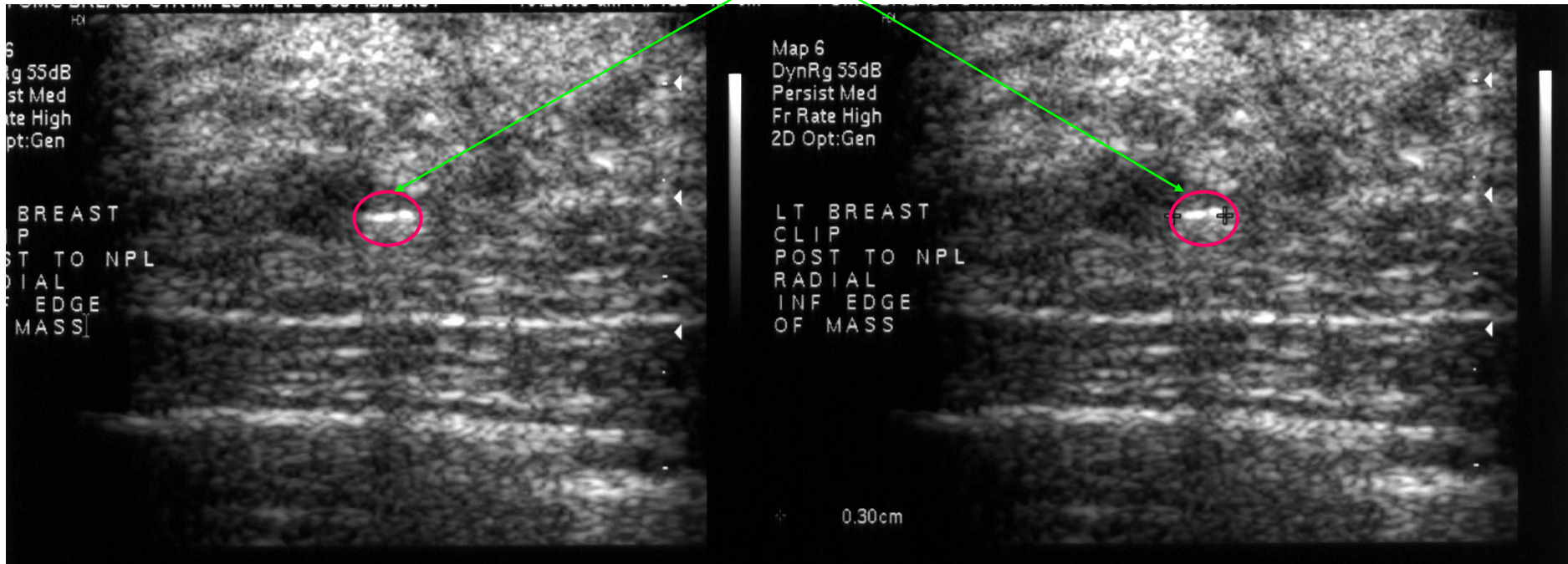


# Case # 9

- 19-year old black female with bilateral palpable masses
- Bilateral US biopsies with bilateral BiomarC placement within masses
- Pathology showed bilateral fibroadenomas
- Patient has multiple fibroadenomas and therefore BiomarC was placed to identify mass which was biopsied in each breasts

# Case #9

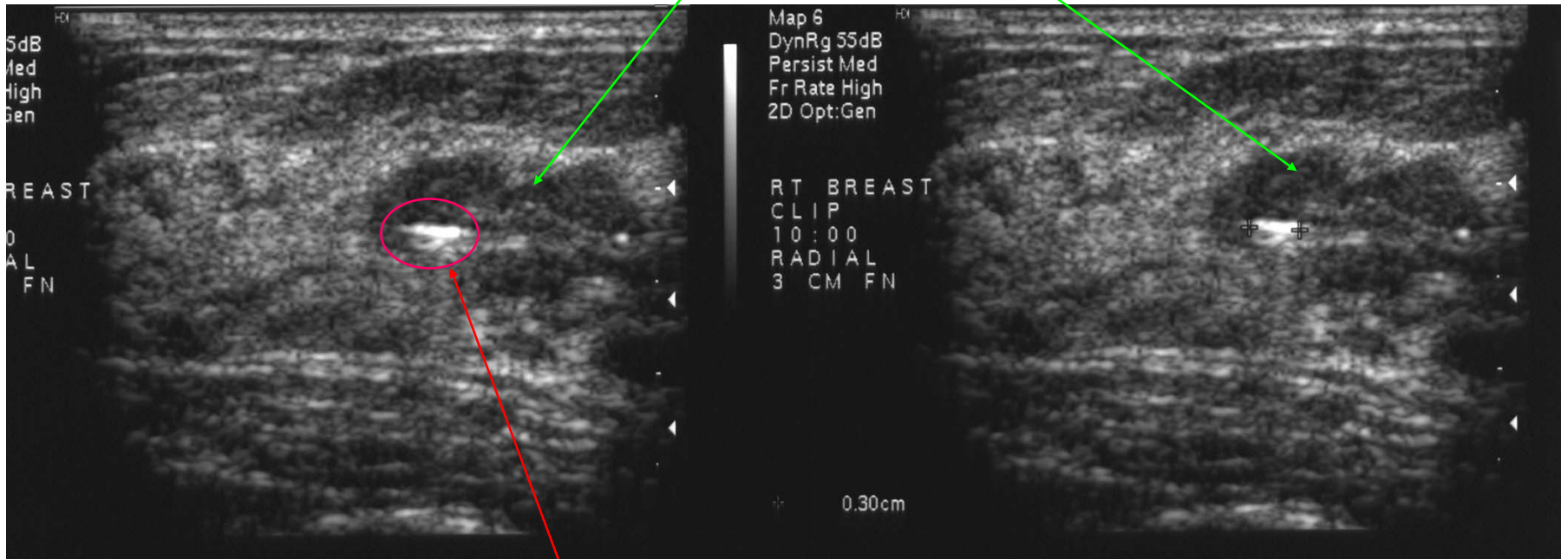
## Left Breast Fibroadenoma



# Case #9

## BiomarC 7 days after biopsy

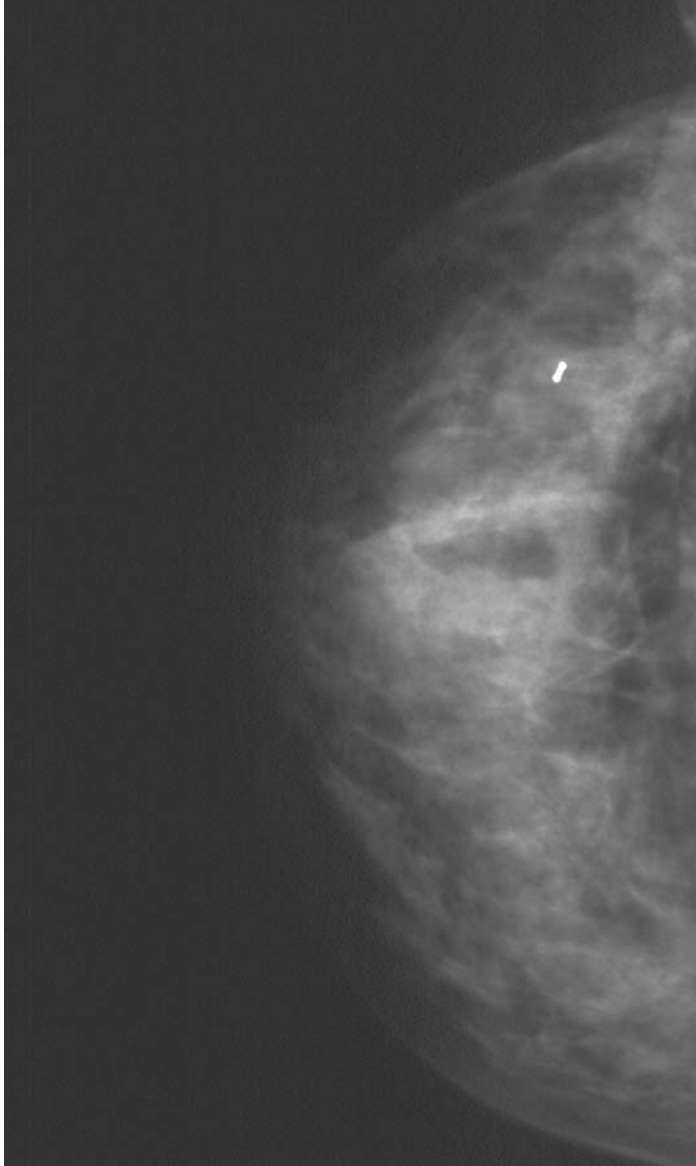
### Right Breast Fibroadenoma



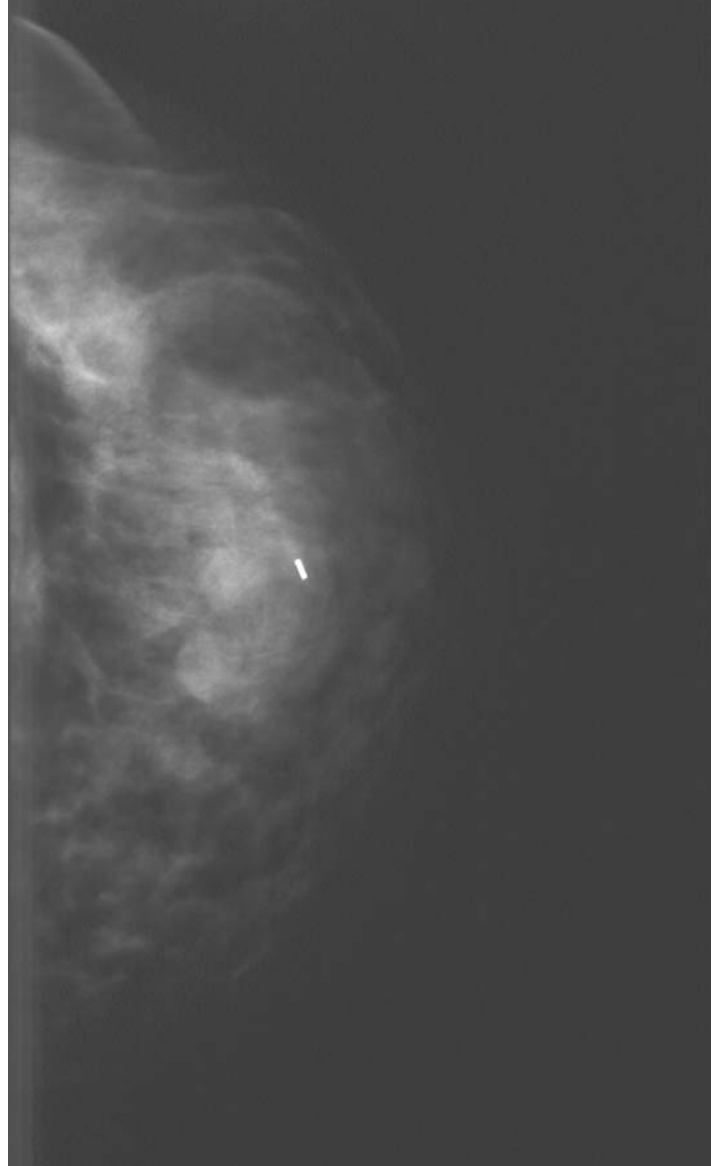
BiomarC

# Case #9

Right CC with BiomarC

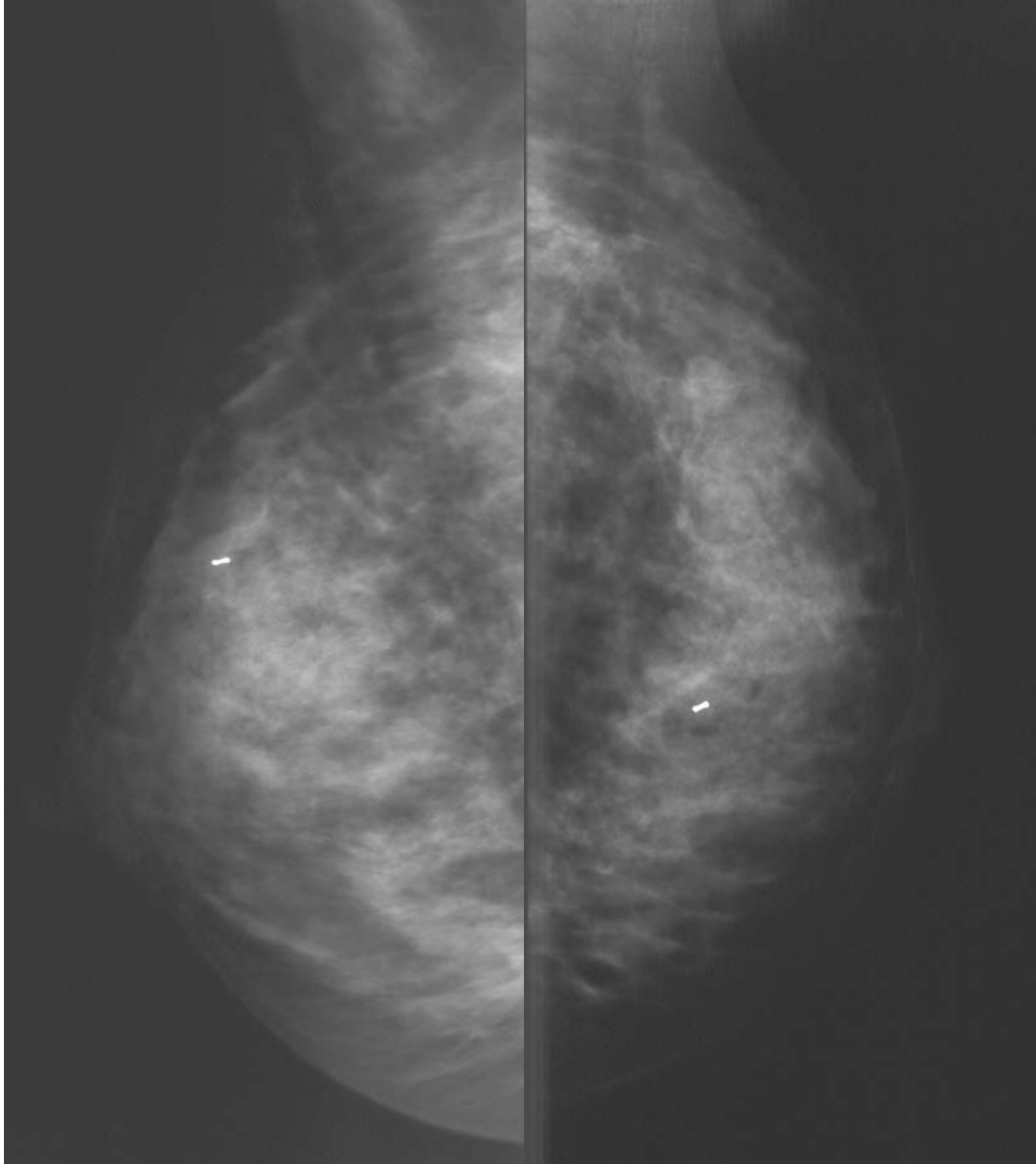


Left CC with BiomarC



# Case #9

Right  
MLO with  
BiomarC



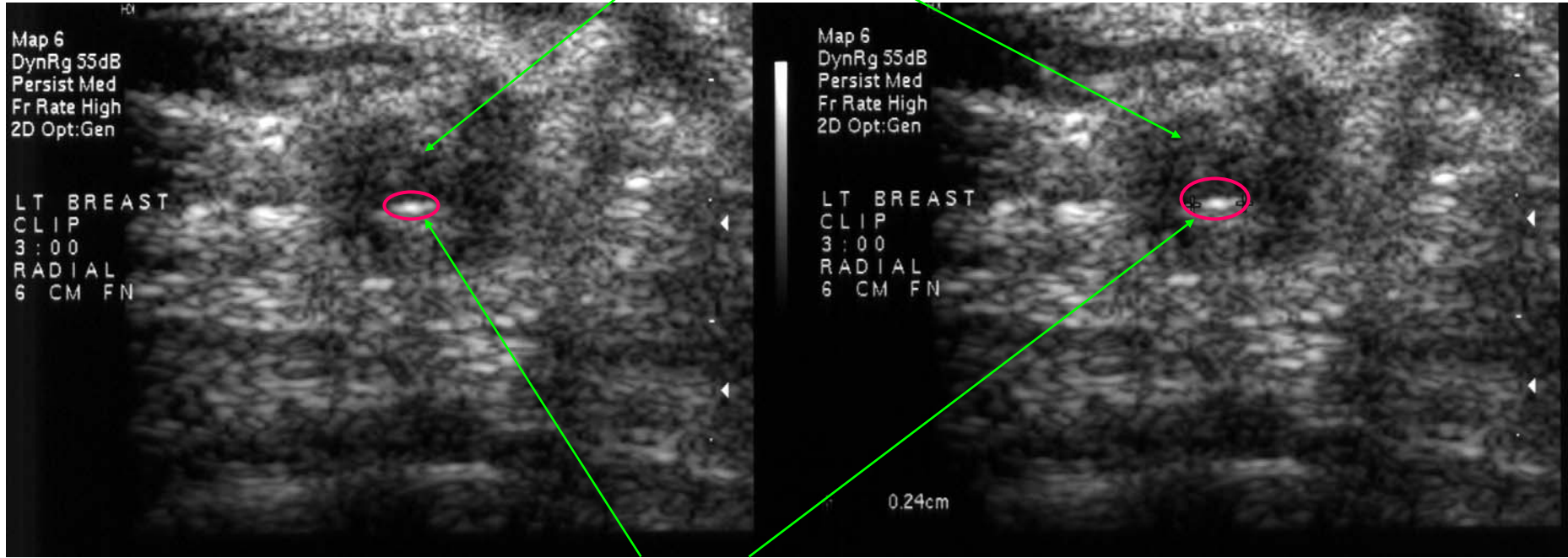
Left MLO with  
BiomarC

# Case #10

- 64-year old white female with left breast mass
- US core Bx at 3 o'clock 6 cm from nipple
- BiomarC breast marker was placed under US guidance
- Pathology showed IDC

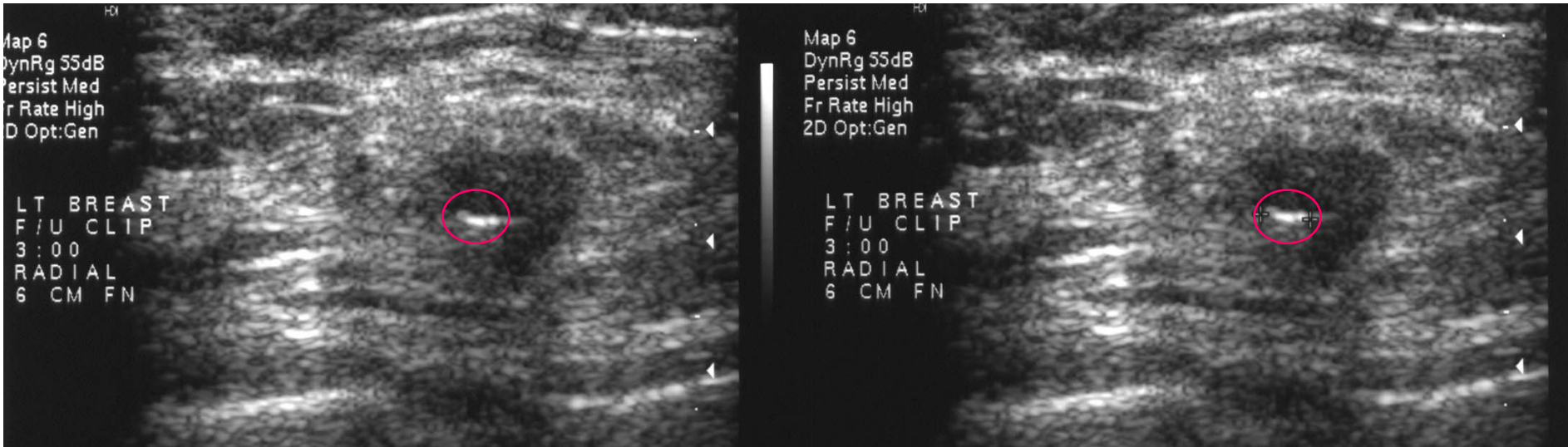


# IDC

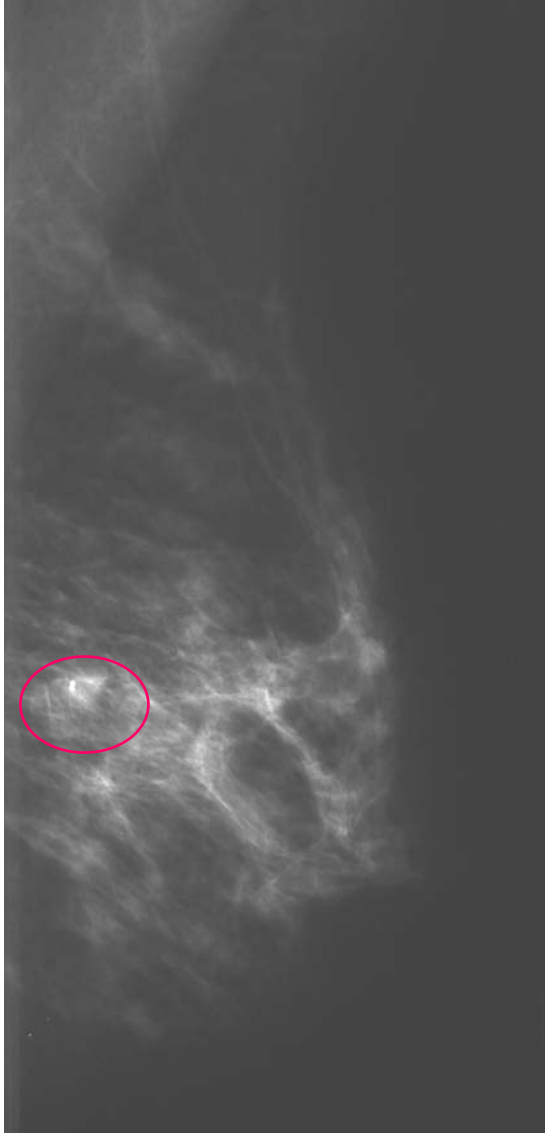


## BiomarC

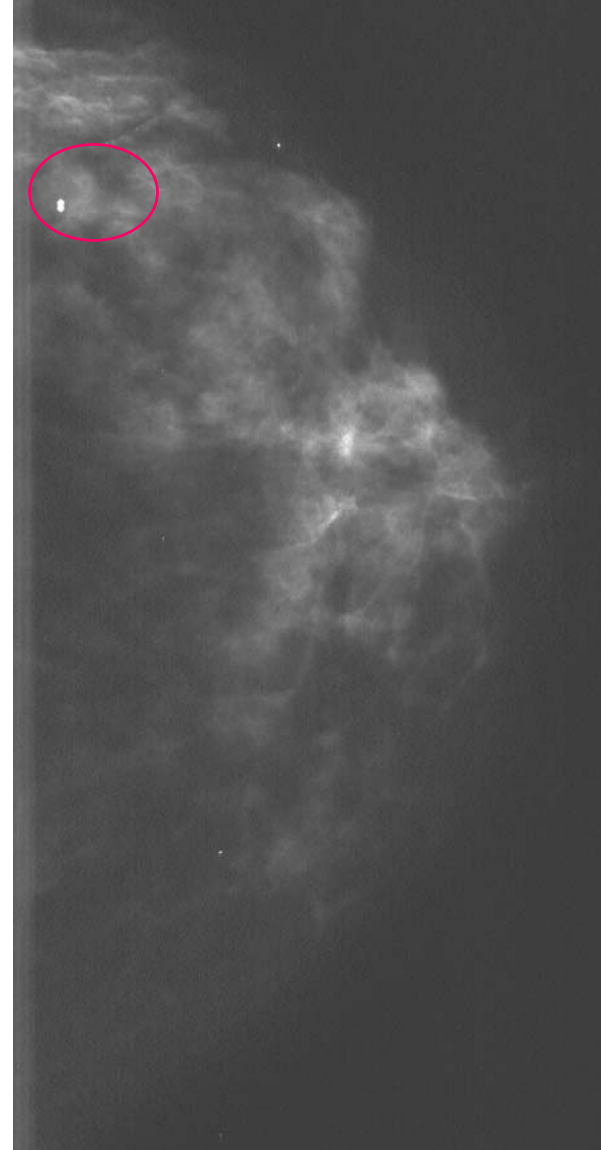
### BiomarC 7 days after biopsy



# Case #10



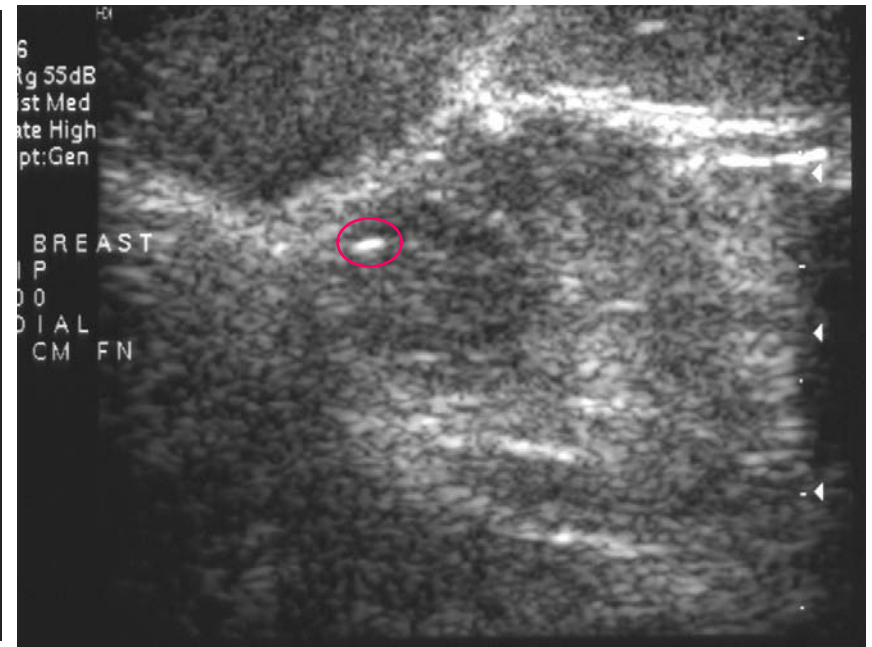
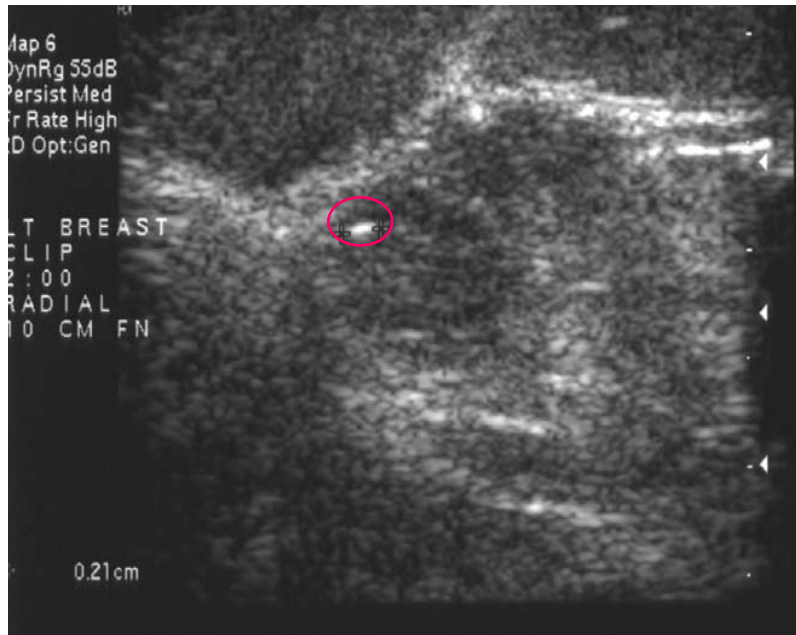
Digital  
Mammo  
with  
BiomarC



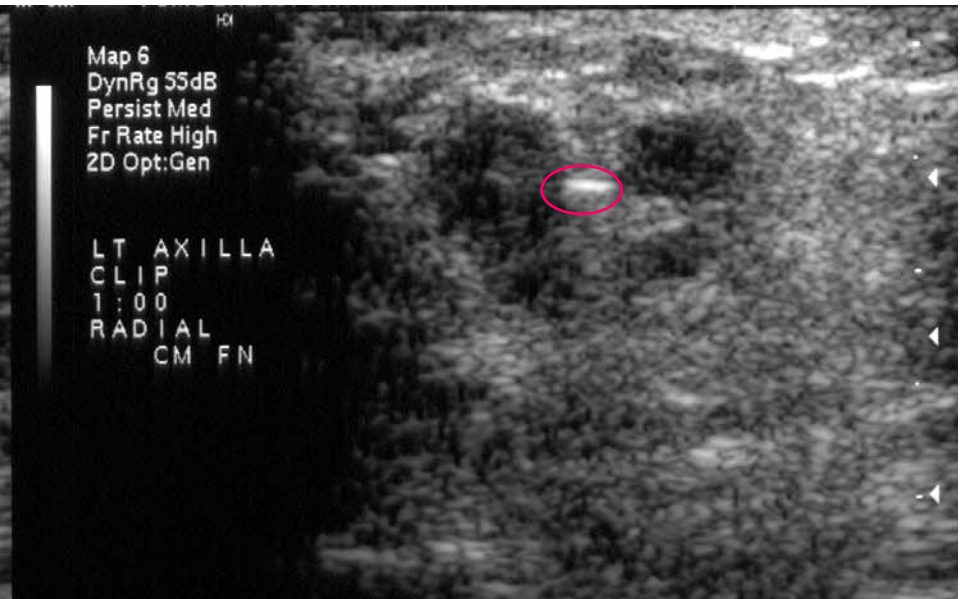
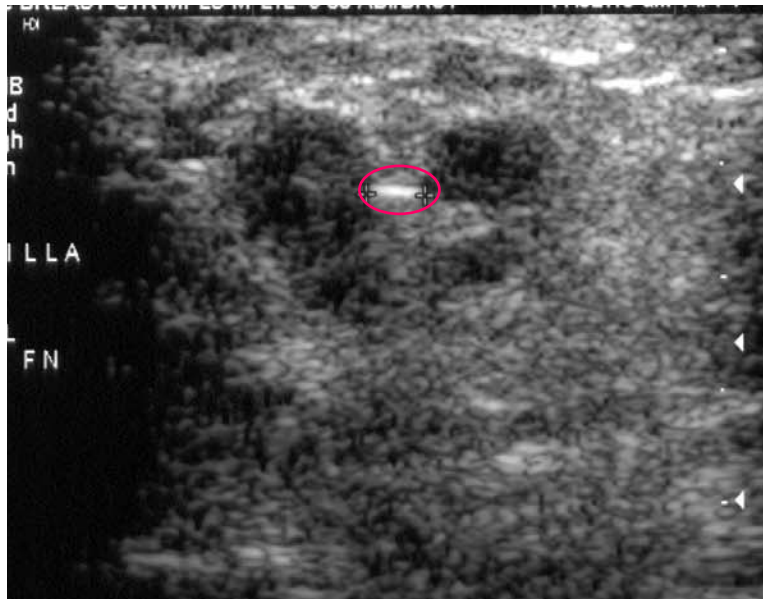
# Case # 11

- 48-year old female with palpable mass in left breast at 2 o'clock
- US biopsy was completed of left breast mass and left axillary lymph node
- 2 Biomarc breast markers were placed: one in the mass and one in the left axillary lymph node
- Pathology was IDC with positive lymph node

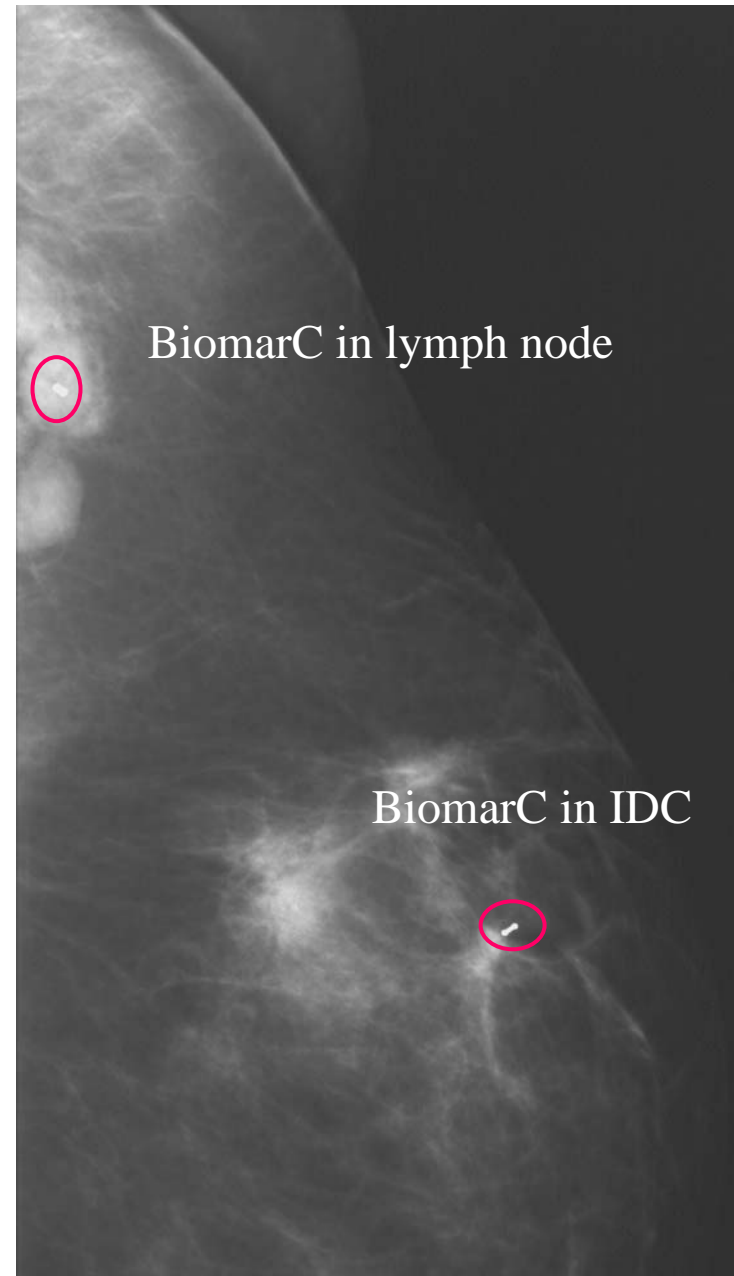
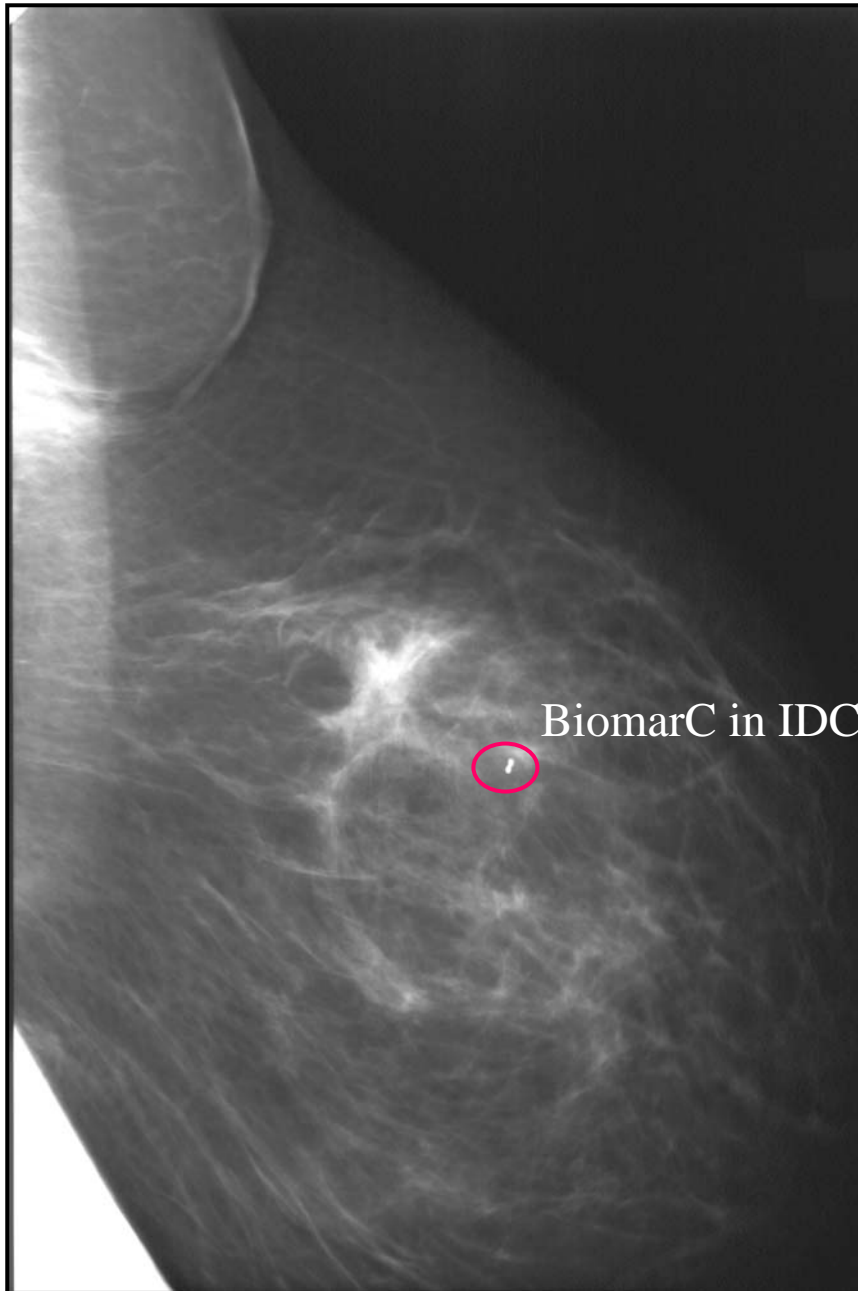
# BiomarC in IDC mass



BiomarC placed in malignant lymph node in left axilla



# Case #11



# Results

- BiomarC has a distinctive barbell shape that is not confused with existing calcifications within the breast tissue
- BiomarC was easily placed under stereotactic guidance thru an existing 11-gauge Bx needle using a hollow side beveled plastic catheter
- BiomarC was placed under US guidance. The delivery system was well-visualized under ultrasound guidance and BiomarC was well visualized during placement
- BiomarC was seen on CT scanning of the breast and caused no artifact on cross-sectional imaging

# Results-Continued

- BiomarC did not interfere with macro-molecular imaging on high field MRI T4 and 1.5T breast imaging. BiomarC also did not interfere with PET or fusion scanning
- BiomarC was placed using MRI guidance in magnetic field using a Philips 1.5T breast grid and Philips biopsy breast coils. Post-digital mammogram showed excellent placement of the BiomarC
- BiomarC can be seen at 7 and 21 days interval if it is placed within the lesion (dark background)
- BiomarC is not well visualized under ultrasound if the marker is not placed directly into the lesion. If the markers is placed in fibrocystic tissue or in fatty tissue the marker was not seen after deployment
- Follow-up digital and film screen mammography taken at 4-5 months on 4 patients showed no migration of the BiomarC (on benign biopsy cases)

# Overall Impression of BiomarC

- It works as well or better than any other breast tissue marker tested in our facility.
- BiomarC does have one large advantage in the future:  
“Macromolecular Imaging on Breast Abnormalities will be possible in the future if the abnormality is marked with BiomarC!”



## References

1. Brenner RJ. Percutaneous removal of post biopsy marking clip in the breast using stereotactic technique. *AJR* 2001; 176:417–419.
2. Rosen EL, Vo TT. Metallic clip deployment during stereotactic breast biopsy: retrospective analysis. *Radiology* 2001; 218:510–516.
3. Liberman L, Sama MP. Cost-effectiveness of stereotactic 11-gauge directional vacuum-assisted breast biopsy. *AJR* 2000; 175: 53–58.
4. Liberman L, LaTrenta LR, Dershaw DD. Impact of core biopsy on the surgical management of impalpable breast cancer: another look at margins. *AJR* 1997; 169:1464–1465.
5. Liberman L, Gougoutas CA, Zakowski MF, et al. Calcifications highly suggestive of malignancy: comparison of breast biopsy methods. *AJR* 2001; 177:165–172.
6. Burbank F, Forcier N. Tissue marking clip for stereotactic breast biopsy: initial placement accuracy, long-term stability, and usefulness as a guide for wire localization. *Radiology* 1997; 205:407–415.
7. Liberman L, Dershaw DD, Morris EA, Abramson AF, Thornton CM, Rosen PP. Clip placement after stereotactic vacuum-assisted breast biopsy. *Radiology* 1997; 205:417–422.

## References *(Continued)*

8. Reynolds HE. Marker clip placement following directional, vacuum-assisted breast biopsy. *Am Surg* 1999; 65:59–60.
9. Lee SG, Piccoli CW, Hughes JS. Displacement of microcalcifications during stereotactic 11-gauge directional vacuum-assisted biopsy with marking clip placement: case report. *Radiology* 2001; 219: 495–497.
10. Burnside ES, Sohlich RE, Sickles EA. Movement of a biopsy-site marker clip after completion of stereotactic directional vacuum-assisted breast biopsy: case report. *Radiology* 2001; 221:504– 507.
11. Philpotts LE, Lee CH. Clip migration after 11-gauge vacuum-assisted stereotactic biopsy: case report. *Radiology* 2002; 222:794–796.
12. Davis PS, Wechsler RJ, Feig SA, March DE. Mi-gration of breast biopsy localization wire. *AJR* 1988; 150:787–788.
13. DiPiro PJ. Disappearance of a localizing clip placed after stereotactic core biopsy of the breast (letter). *AJR* 1999; 173:1134.
14. Esserman LE, Cura MA, DaCosta D. Recognizing pitfalls in early and late migration of clip markers after imaging-guided directional vacuum-assisted biopsy. *RadioGraphics* 2004; 24:147-156.